BIERMANN MEDIZIN

# World Ophthalmology News

World Ophthalmology Congress 2012 | 16 – 20 February | Abu Dhabi

## Tackling ROP

The KIDROP-experience shows that tele-ophthalmology is a cost effective possibility to spread ROP-screening programmes into the ural areas of India. ➠ Page 3

## Therapies for AMD

Noumerous new medical therapies for wet age-related macular degeneration are under investigation. This is one of the most rapidly evolving fields in ophthalmology. ➠ Page 8

## Tears and Bubbles

Femtosecond laser flap complications are very rare and often linked to the surgical technique. Usually they can be handled without consequences for the patient. ➠ Page 11

# An Enriching Experience

## The World Ophthalmology Congress 2012 in Abu Dhabi: Outstanding Speakers, Ultra-Modern Exhibition Centre, Traditional Hospitality

ABU DHABI [jp] – For the first time the World Ophthalmology Congress (WOC) will be hosted in the Middle East and Africa Region.

The destination is definitely new to most of the participants of ophthalmic congresses: Abu Dhabi, the capital of the United Arab Emirates (UAE) will be the heart of the ophthalmic world from 16 to 20 February 2012. Never before such a prestigious international medical meeting has taken place in the Middle East and Africa Region.

### Another World-Class Congress

Dr. Abdulaziz AlRajhi, this year's congress president, is confident, that the WOC 2012 "will prove to be an enriching experience to all the participants and delegates". High quality scientific content from more than 2000 internationally recognized speakers, a rapidly evolving city with an ultra modern exhibition centre and the unique Arab culture: These are the elements that will contribute to a high standard congress. Dr. Bruce E. Spivey, president of the International Council of Ophthalmology is sure: "You can expect another world-class congress, matching those in Berlin, Hong Kong and Sao Paulo."

ADNEC

The heart of the ophthalmic world from 16 to 20 February: The Abu Dhabi National Exhibition Center

Chairman of the scientific programme is Prof. Dr. Peter Wiedemann who coordinates a programme that will cover 35 subspecialty and topic areas. More than 45 sessions will be organized by the International Council of Ophthalmology members and participating societies. Symposia, case studies, debates, panel discussions, video sessions and interactive lectures will give every congress attendee the possibility to gain insight into the latest developments in their respecitve topic. Leading ophthalmologists around the world will coordinate, moderate oder chair the sessions.

### Ideal Setting

Wiedemann encourages the colleagues from all over the world to attend the WOC 2012: "A modern city combined with a rich cultural heritage, Abu Dhabi promises to be an ideal setting for scientific communication and innovation."

### See, Hear and Taste the Culture

The local organizers as well as representatives of the Abu Dhabi Tourism Authority also recognize the congress as an opportunity to present the capital of the United Arab Emirates and the wider emirate to a worldwide audience. Members of the Middle East Africa Council of Ophthalmology (MEACO) strive to ensure that all WOC visitors experience a stimulation environment. Prince Abdulaziz Ahmed Abdulaziz Al Saud, chairman of the MEACO board, promises culturally rich social events: "You will see, hear and taste the unique Arabian culture."

### Luxury and Style

A great opportunity to do so will be the cultural night on 17 February at the Abu Dhabi Emirates Palace: Luxury and style, infused with traditional values of hospitality and respect will be the source of a memorable experience. ▪

# Dealing with Small Pupils

## Mechanical Stretch, Iris Hooks, Malyugin Ring

SUNDERLAND – The definition of a small pupil depends on the degree of experience of the surgeon, and also on the degree of surgical difficulty expected to be encountered.

An experienced surgeon may be happy to operate with a 3-4 mm pupil in a straightforward case, but may be unhappy with a 4.5 mm pupil if dealing with a rock hard cataract. The problems caused by a small pupil are not confined to difficulties removing the nucleus without damaging the iris margin. A smaller pupil allows less light to enter the eye, and so the red reflex may be poorer with smaller pupils and the threshold for use of a capsule staining dye is therefore lowered.

David Allen

Small pupils may be due to posterior synechiae from previous inflammation or previous miotic use (rare now but was common in the past). The condition may in other cases be due to some other concurrent disease/medication e.g. pseudoexfoliation, tamsulosin use, or it may simply be a small pupil.

Always check to see if there are posterior synechiae and carefully break these (including at mid-stroma if patient has been on long term miotic).

Simple mechanical pupil stretch with 2 instruments can be effective in many cases (figure 1). It is important to stretch by taking the instruments almost into the angle. One problem is that the pupil may then re-constrict or wave in the breeze because of multiple sphincter rupture.

Experience with IFIS from tamsulosin use has shown the value of intracameral alpha agonists either at the outset or during surgery. We favour phenylephrine diluted in BSS (others advocate epinephrine). The contents of 1 minim of 2.5% phenylephrine (Bausch & Lomb) added to 1-2 mL of BSS injected into the AC can give added dilatation, and certainly diminishes or prevents re-constriction and also prevents iris prolapse.

In all cases consider reducing your fluidics parameters. A high aspiration flow rate increases the risk that you will aspirate the pupil margin in small pupil cases. A high vacuum then makes it much more likely that you will damage the iris tissue if you do catch it, and this can cause problems for the surgery and problems for the patient afterwards.

For some cases it is desirable to mechanically dilate and then in some way to fix the pupil. We initially learned from vitreo-retinal surgeons to use iris hooks. If you use iris hooks ensure that your incisions in the cornea to place the hooks are very peripheral (there should be bleeding at each incision) and horizontal (figure 2). This ensures that you are pulling the pupil margin peripherally rather than upwards.

Some hooks come in packs of 5 – the 5th one is meant as a 'spare' in case you drop one. However, you can also plan to use 5. When using 4 make a 'diamond' pattern rather than a 'square' – in other words one hook should be placed under the incision so that you get maximum retraction where you are entering the eye with the phaco tip (figure 3). Try to space the incisions/hooks as symmetrically as possible.

continued on page 2 ➠

continued from page 1

More recently a very simple but ingenious device from Russia (Malyugin ring) has become very popular. Personally I find this easier to use than hooks – although it is not without its difficulties. In all cases where the pupil has been stretched consider using additional anti-inflammatory medication post operatively to reduce the chances of uveitis/fibrin.

Figure 1: Use of two instruments to stretch a small pupil. Note, stretch out almost into the AC angle.

Figure 2: Placing peripheral corneal incisions for iris hooks. Note, three incisions already made and their position shown by small amount of bleeding.

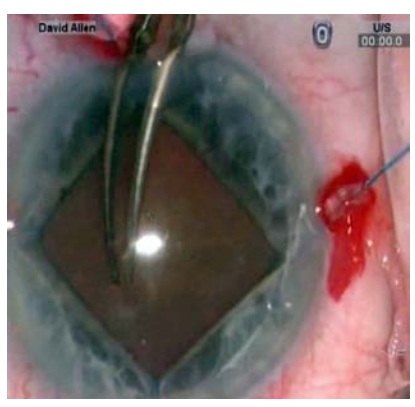

Figure 3: Iris hooks in 'diamond' configuration allowing maximum dilatation in sub-incisional area.

### Further Notes on the Particular Problems of IFIS

At the turn of the year 2004/05 we became aware of a 'new' phenomenon – the intra-operative floppy iris syndrome (IFIS). While the exact mechanism underlying this problem is still uncertain, we do know that it is relatively common. The biggest risk factor for IFIS is the current or previous use of the drug tamsulosin. 1-2% of the cataract surgery population is in this category. Although some surgeons have been concerned about patients taking other α1a blocking agents, the risk of experiencing IFIS in patients with tamsulosin is 40 times that in patients using other blockers.

These are not simply patients with small pupils. The iris behaviour is quite specific, and some simple measures good for 'normal' small pupils such as pupil stretching are positively contraindicated in IFIS patients.

### Our Experience of IFIS

Experience with 30 consecutive eyes in late 2005/early 2006 in patients taking Tamsulosin:
50% of patients will dilate well, but
50% of these will subsequently constrict during surgery
35% will be moderately dilated
15% will be poorly dilated
Manvikar & Allen JCRS 32:1611-14 2006

**Thu, 16 February 13.00 – 14.30 hrs**
**Hall 10**
**Session: CAT - Detour: roadblocks to routine phaco**

**Author:** David Allen
Consultant Ophthalmologist
Sunderland Eye Infirmary
England
E-Mail: allen401@btinternet.com

## 10 Pearls for Dealing with IFIS

It is seen in 2/3 patients using Tamsulosin. IFIS with Tamsulosin 40* than with other α1 blockers. Also with hypertension (Odds Ratio 2.2) but not with diabetes

▶ **1. Assume there will be IFIS if the patient takes tamsulosin.**

▶ **2. It may affect any patient, therefore you and your staff need to be prepared.** Some have advocated pre-treatment with Atropine – either on the day or for 2-3 days prior. This disrupts normal routine and is not as effective as intra-cameral phenylephrine (IPE)

▶ **3. Pre-treating with Atropine is not advised.** Phenylephrine is a potent α agonist. Placing this in direct contact with iris tissue appears to produce the maximum dilator tone.

▶ **4. Use appropriately diluted (contents of 1 minim 2.5% in 1-2mL BSS) intracameral phenylephrine**
**- 'prophylactically' at the outset**
**- or if pupil begins to constrict**
**- or if iris begins to prolapse**
Incision placement and size are important.

▶ **5. Ensure the inner incision edge is anterior to the iris plane.**
A smaller phaco-needle bore may help to avoid engaging iris

▶ **6. Try to use 0.9/0.8mm (20/21G) phaco needles.**
Some have advocated use of dispersive OVD (Viscoat) placed on the iris and at pupil edge. Arshinoff has modified his 'ultimate soft shell technique' to create a bridge of dispersive OVD in the AC

▶ **7. Think about and use the properties of viscoelastics to assist you.**
High flow causes turbulence and high vacuum causes iris damage if caught

▶ **8. Use moderate or low fluidics (recommend 20-30 mL/min, 200-300 mmHg, 80-90 cm bottle height).**
Despite everything, some pupils remain too small for safe phaco.

▶ **9. Do NOT stretch small pupils of Tamsulosin patients – use a physical pupil expander, Iris hooks or Malyugin ring.**

▶ **10. Remember the other 9 pearls, particularly number 2.** ■

# Current Status of Phakic IOL

## Doubts are Justified – but New Lenses Arouse Expectations

FRANKFURT – Endothelial cell loss or iatrogenic cataract discourage many surgeons from using phakic lenses. New, modern PIOL may offer new solutions to their questions.

Trials comparing corneal refractive surgery with phakic intraocular lenses (PIOL) reveal the superiority of the latter in terms of quality of vision, while other parameters like stability, safety and efficacy are comparable.[1,2] However, PIOL today are most often used in patients, for whom refractive corneal surgery is not applicable due to high ametropia, large pupils and thin or irregular corneas. Known severe long-term complications like the endothelial cell loss or cataracts discourage many surgeons from using phakic lenses as an equal procedure next to laser refractive surgery.[3,4]

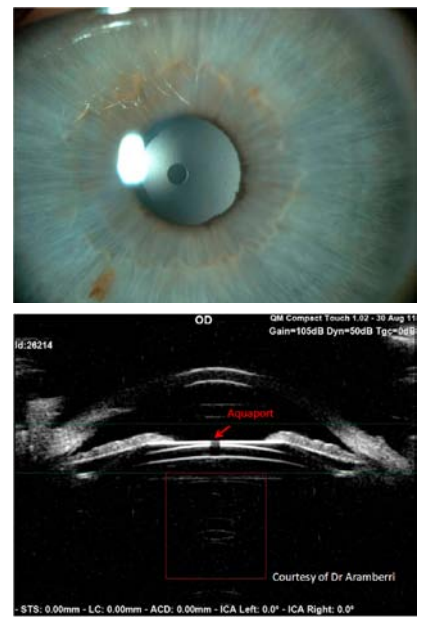


Figure 1: Slit lamp and UBM imaging of the ICL (STAAR) with central hole ("aquaport").

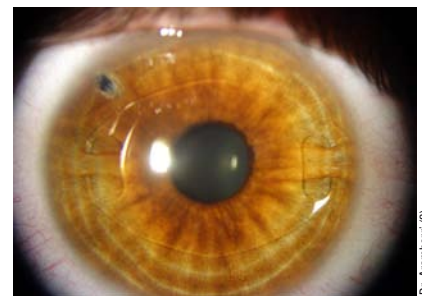

Dr. Aramberri (3)

Figure 2: Iris fixated Artisan lens (Ophthec), 2 years post implantation.

The question arises, whether these doubts, resulting from many failures in the development of different PIOLs, are still appropriate when modern PIOL are used? The answer is yes. And no. Doubts are justified, but the negative experiences with former implants are not 100% applicable to today's lenses.

The most dreaded complication of posterior chamber PIOL is iatrogenic cataract, induced by contact between the PIOL and the natural lens due to insufficient vaulting and/or modified aqueous humour fluidics. Schmidinger et al[5] show a nearly linear and continuous decrease in the distance of the ICL V4 (STAAR) and the natural lens in 84 patients. From 466±218 µm directly after surgery the distance decreases to 184±159 µm after 74.1±23.1 months. The resulting clinical significant anterior subcapsular cataract rate in their retrospective trial cohort was 28% after 44 months. 17% of the patients underwent explantation of the PIOL following cataract surgery. Inadequate clearance between the natural lens and the PIOL was a significant predictor for anterior subcapsular cataract formation. The latest design evaluation of the ICL provides a central hole in the optic to prevent pupillary blocking and to enhance the aqueous humour fluidics in the gap between the ICL and the lens to reduce cataract formation. (Figure 1) First results by Shimizu et al[6] show very good short-term visual results, comparable to other phakic lenses, proving the optical practicability of the central hole. Although this is a very promising implant, longer follow ups are needed to evaluate the cataract rate and long term vaulting stability.

Alcon

Figure 3: Cachet phakic angle supported lens.

In opposite to this very new posterior chamber PIOL, the long-term results of today's most commonly used anterior chamber iris-fixated PIOL (Artisan, Ophthec, figure 2) are well known. The visual outcomes are excellent, even in toric patients. Sizing of the implants is, contrary to posterior chamber or angle-supported anterior chamber IOL, not an issue. The weak point of iris-fixated PIOL is the endothelial cell loss. Studies show mean rates of up to a maximum of 14.05% after 5 years.[4] Outliers, however, also need to be taken into consideration.

The history of anterior chamber angle-supported PIOL is mainly a history of failures. Even though visual results have been very good, severe endothelial cell losses, pupil ovalizations, synechia and inflammations have led to the withdrawal of almost every implant.[3,4] The latest development in this field is the Cachet PIOL (Alcon, figure 3), a single-piece, foldable soft acrylic IOL. Visual results are very good, as published three-year FDA trial data by Knorz et al[7] show. For example: UDVA was 20/40 or better in 101 (97.1%) and 20/20 or better in 48 (46.2%) of 104 patients. The residual refractive error was within ±0.50 D of target in 82 patients (78.8%).

Apart from that, all other known severe complications from angle-supported anterior chamber lenses seem to be under control. No pupil ovalization, pupillary block, or retinal de-tachment was observed after three years.[7] Looking particularly at the endothelial cell loss data leaves refractive surgeons optimistic. The annualized percentage loss in central and peripheral endothelial cell density from 6 months to 3 years was 0.41% and 1.11%, respectively.[7] The natural endothelial cell loss in adults is about 0.3 to 0.6%. Both, visual acuity and endothelial cell loss numbers, remain stable when looking at the, yet unpublished, 5-year follow up. However, longer follow up is required here as well, to evaluate the long-term safety.

### The Ideal Phakic Lens

The ideal phakic lens has to fulfil different requirements: Lenses should be foldable to allow for astigmatism-neutral implantation and thus predictable refractive outcome. Lens design, positioning and material should not induce any short- or long-term intraocular damage; endothelial cell loss and cataract formation are especially an issue here. If lenses fulfil these needs, there is no reason, why PIOL should not be used as an equal procedure next to corneal laser refractive surgery. Eventually PIOL have one major advantage compared to excimer laser surgery: their reversibility! ■

### References

1. Vilaseca M, Padilla A, Pujol J, Ondategui JC, Artal P, Guell JL. Optical quality one month after verisyse and Veriflex phakic IOL implantation and Zeiss MEL 80 LASIK for myopia from 5.00 to 16.50 diopters. J Refract Surg 2009;25:689-698.
2. Barsam A, Allan BD. Excimer laser refractive surgery versus phakic intraocular lenses for the correction of moderate to high myopia. Cochrane Database Syst Rev 2010:CD007679.
3. Guell JL, Morral M, Kook D, Kohnen T. Phakic intraocular lenses part 1: historical overview, current models, selection criteria, and surgical techniques. J Cataract Refract Surg 2010;36:1976-1993.
4. Kohnen T, Kook D, Morral M, Guell JL. Phakic intraocular lenses: part 2: results and complications. J Cataract Refract Surg 2010;36:2168-2194.
5. Schmidinger G, Lackner B, Pieh S, Skorpik C. Long-term changes in posterior chamber phakic intraocular collamer lens vaulting in myopic patients. Ophthalmology 2010;117:1506-1511.
6. Shimizu K, Kamiya K, Igarashi A, Shiratani T. Early clinical outcomes of implantation of posterior chamber phakic intraocular lens with a central hole (Hole ICL) for moderate to high myopia. Br J Ophthalmol 2011.
7. Knorz MC, Lane SS, Holland SP. Angle-supported phakic intraocular lens for correction of moderate to high myopia: Three-year interim results in international multicenter studies. J Cataract Refract Surg 2011;37:469-480.

**Thu, 16 February 16.30 – 18.00 hrs**
**Hall 10**
**Session: CAT - Hot topics in cataract surgery**

**Authors:** Oliver K. Klaproth, Thomas Kohnen, MD, PhD, FEBO
Corresponding Author: Thomas Kohnen,
Department of Ophthalmology
Goethe University
Frankfurt am Main, Germany
E-Mail: kohnen@em.uni-frankfurt.de

# The KIDROP Experience in India

## Tackling ROP in Middle-Income Countries with Cost-Effective Tele-Ophthalmology

**BANGALORE – The need for telemedicine in Retinopathy of Prematurity (ROP) in middle-income countries like India is born out of the skewed demand and supply problem plaguing ROP management, the largest cause of infant blindness worldwide.**

Anand Vinekar, MD, FRCS

Of the 27 million live births annually in India, about 8.8% are born below 2000 grams and are at risk of ROP. However, a majority of these infants are born in rural areas and remain unscreened. With less than 500 retinal surgeons and 20 ROP specialists, there is a huge unmet need for ROP management in India.

### Asia's First Tele-ROP Screening Programme

In 2008 we started Asia's first tele-ROP screening programme in Southern India to cover unscreened rural neonatal care centers in the state of Karnataka. Under this KIDROP (Karnataka Internet Assisted Diagnosis of ROP) programme, technicians were trained to image, interpret, store and upload images taken on a mobile wide-field digital retinal camera, the Retcam Shuttle (Clarity MSI, Pleasanton, CA, USA) on to a secure server for experts to review remotely. Together with our technology partners we developed a comprehensive software-hardware platform, which allowed images to be viewed on the smart phone or the PC using the lossless Automated Binary Optimization (ABO) compression technology (patented). Images were also graded by these technicians and validated against binocular indirect ophthalmoscopy by the ROP expert.

The KIDROP programme currently serves 51 neonatal intensive care units (NICU) in rural and semi-urban regions and runs on a non-profit grant by the Institute. 18 of these centers are in a remote zone 500 kilometers away and are co-managed in a public private partnership (PPP) with the State Government. In this PPP the Government has granted USD 0.52 million (2009-2012) to set up two zones that cover six districts each. Our contribution will include free training, image reading and treatment. The government will provide for the equipment, its maintenance and financial compensation of the technicians in the outreach.

Anand Vinekar (4)

Figure 1: Technicians imaging as project manager uploads.

Thus far, we have completed over 25,000 imaging sessions and recruited over 6500 infants into the ROP screening programme in more than twelve districts of Karnataka state covering two zones, each having a radius of care of around 400 kilometers. In this study, we present a cost-utility evaluation of the KIDROP programme. We used the financial audited data in our study to complete an economic evaluation that employs Analytic Hierarchy Processing (AHP), a multi criteria decision model for comparing the KIDROP strategy (which uses a single Retcam shuttle for 6 districts) to three alternate strategies of ROP screening.

### Alternate Strategies

The three alternate strategies were hypothetical and were:

1) Parents in the rural outreach are educated, sensitized and urged to travel with their infants to the city for screening at designated sites.

2) Rural infants are to be screened at their respective district hospitals by trained experts using indirect ophthalmoscopy one day a week who travel from their city based practices.

3) Screening is performed by trained non-physicians using Retcams at each district headquarters. The last strategy is similar to KIDROP but needs to have several Retcams servicing each district.

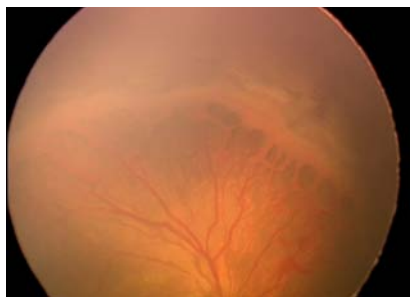

Figure 2: A PROP in a rural infant.

### Criteria for Cost-Effectiveness

Cost-effectiveness in all four strategies was computed using three criteria:

1) Organizational costs: costs incurred by the 'provider' (who could be a private or a public enterprise or a public-private partnership)

2) Burden weight: burden to the parents or guardians of the child including direct and indirect costs

3) Disease coverage: number of 'disease susceptible' as a proportion covered under the strategy.

Using AHP, the overall ranks comparing these strategies were then calculated by the matrix multiplication of the AHP Modified Weights matrix with that of the Priority Weights matrix. These ranks measured the "best methodology" between these strategies. Sensitivity analysis and the analysis of uncertainty were also performed to evaluate the maximum and minimum budgetary requirements in each strategy. 'Best case', 'worst case' and 'balanced scenarios' were computed against each strategy and intervention to determine the best strategy in these situations.

When the maximum patient coverage was considered as the goal ('the best case scenario") (which should be the aim of any screening intervention in the community), the best ROP screening strategy for all three scenarios i.e. the provider's perspective (funding organization), the patient's perspective and a 'balanced scenario' was the KIDROP model. In the poorest coverage ('worst case'), best ROP screening strategy for the funding organization was the KIDROP model, but from the patient's perspective and for the balanced scenario it was the multiple Retcam model.

### Best Screening Strategy in Four out of Six Situations

Hence, the KIDROP model ranked as the 'best screening strategy' in four out of six situations. In all situations tele-ROP ranked higher than the other interventions where the specialist or the patient had to travel for screening.

Figure 3: Infants sharing an incubator in rural NICU.

The lowest rank in all six situations was the strategy where mothers had to travel to the city with their infants for ROP screening. This was the strategy that had the lowest cost but produced the poorest coverage, since most parents in rural areas were daily wage workers and belonged to the lower economic strata making travel costs with the family a heavy burden on their resources.

The fact that repeated visits are needed before discharge from the screening programme, further adds to problem of travelling which compounds the costs for the family. Poor compliance to complete the screening meant higher risk of blindness. The multiple Retcam stra-tegy had the best coverage but caused a larger financial burden on the organizations that fund and manage the programme. In a public private joint enterprise, it was more likely that funds would be limited and needed prioritization. In our own setting, we were able to convince the Government to fund only one Retcam per zone.

### Economic Impact

The economic impact of the KIDROP programme can be indirectly measured by evaluating the blindness prevention quotient in financial equivalents. Thus far 512 children have received vision restoring laser treatment. The return on investment in the national perspective may be calculated as follows: Each of these 512 infants will survive to an average of 65 years (average life expectancy) and earn approximately USD 900 per annum (per capita income). This is a federal saving of over USD 25 million! All this for an investment of less than USD 250,000 ! The social returns are, of course, priceless.

As we previously reported, barriers of cost and infrastructure must be met. The cost of the camera alone is currently approximately USD135,000 in India. The greatest barriers, however, are the "mental barrier" of the care-givers created by a mixture of poor awareness, inadequately trained personnel and unwillingness to adapt to innovation. However, there is hope that with time, patience and passion, these barriers can be overcome.

### A Viable Model

In conclusion, tele-ROP is a viable model in middle-income countries. The cost utility analysis comparing the KIDROP model with other alternate strategies indicates that the KIDROP model, which uses a single Retcam shuttle to service a zone of roughly 300-400 kilometers radius in six districts using non-physicians (trained technicians) is the most cost-effective method of providing the standard of care in ROP screening in centers which are rural or peripheral with limited access to health care given the current scenario of limited experts and funds. Each country with similar demographic and financial milieu as India must explore tele-ROP as a viable financial model and customize it to suit their local needs. ■

**Thu, 16 February 13.00 – 14.30 hrs**
**Hall 7**
**Session: PED - Pediatric Retina**

**Author:** Anand Vinekar, MD, FRCS
Associate Professor & Head
Department of Pediatric Retina
Narayana Nethralaya Postgraduate Institute of Ophthalmology
Banglore, India
E-Mail: anandvinekar@yahoo.com
www.narayananethralaya.org
www.facebook.com/KIDROP

**Acknowledgements: The KIDROP teams at Narayana Nethralaya Postgraduate Institute of Ophthalmology, Bangalore and in North Karnataka and The National Rural Health Mission (NRHM), Min. of Health and Family Welfare, Government of Karnataka, India.**

## References

Vinekar A.: IT-enabled innovation to prevent infant blindness in rural India: the KIDROP experience. Journal of Indian Business Review; 2011; 3(2):98-102.

Govindrajan, V.: A telemedicine innovation for the poor that should open eyes. Harvard Business Review 2010 November 7, available at: http://blogs.hbr.org/govindarajan/2010/11/

Min of External Affairs Publication, Government of India: Unique experiment in Tele-medicine: Tele-ophthalmology provides a new hope in preventing infant blindness in rural infants, India Perspectives, 2010;24;70-1.

Kreatsoulas, J.: Progress in ROP management through Tele-ophthalmology. Retina Today, 2010; December.

Vinekar, A.: The ROP challenge in rural India: preliminary report of a telemedicine screening model. (In) International Experience with Photographic Imaging for Pediatric and Adult Eye Diseases. Retina Physician 2008, Supplement 9-10.

(KIDROP updates are available on www.facebook.com/KIDROP )

# Phaco Nightmares and Worst Case Scenarios

## A Video Based Symposium

CHENNAI – Various complications can occur during phako surgery, but the worst case scenarios are dropped lenses and nuclei. This course will present various crazy cases and their management.

The usage of diamond tipped forceps in the removal of dropped intraocular lenses (IOL) will also be shown. Difficult cases like subluxated lenses, posterior polar cataracts, colobomas and complications will be presented in videos. For the management of the intraoperative floppy iris syndrome (IFIS) the implantation of the glued IOL will be taught with endocapsular rings and capsule retractors.

The unsteady capsular bag has to be handled delicately. If the surgeon is not careful, a PC IOL could drop into the vitreous cavity. So the ophthalmic surgeon should know how to handle these situations. Repositioning an IOL and refixating the bag are maneuvers the experienced surgeon has to know. This symposium will teach all there is to know on these subjects through videos.

### How to Use an IOL as Scaffold

The use of an IOL as scaffold is another trick the attendees of the session will learn: A foldable IOL is used as a scaffold for preventing the nucleus fragment from descending into the vitreous in cases of posterior capsular ruptures (figures 1 and 2). After removing the vitreous in the anterior chamber by anterior vitrectomy, a three piece foldable IOL is injected via the existing corneal incision with one

Amar Agarwal

haptic above the iris and the other haptic extending outside the incision. The nucleus is emulsified with the phacoprobe above the IOL optic. Cortical cleaning is done and the IOL is then placed over the remnants of the capsule in the ciliary sulcus. This can be performed in eyes with moderate to soft cataracts. This technique helps to avoid the extension of the corneal incision and thereby limits the induced astigmatism.

### The "Glued IOL" Technique

"Glued IOL" as a technique for PCIOL fixation in eyes with absent or insufficient capsular support was first proposed in 2007. Since then a large number of cases has been operated on with this technique with the longest follow-up being more than 3.5 years. The basic technique starts with creating two lamellar scleral flaps and retrieving the haptics of the IOL through sub-flap sclerotomies (1 mm from the limbus) using 23 G Micro-Surgical Technology (MST) forceps. The haptics are then fixed trans-scleral ly into scleral pockets created at the edge of the flap with a 26 G needle (figure 3). With the help of fibrin glue the scleral flaps are then stuck down. It is ideal to use either a 23 G infusion cannula (which is easy to use for anterior segment surgeons as well) or an

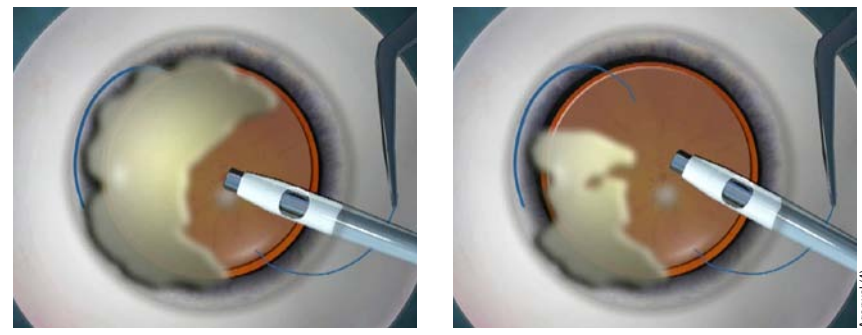

Figures 1 and 2: An IOL may be use as a scaffold to prevent the nucleus from dropping into the vitreous in case of a posterior capsular rupture.

Agarwal (4)

anterior chamber (AC) maintainer during the course of the procedure to keep the globe well formed. The intervention may be performed as an injectable glued IOL technique using a three piece foldable IOL. This allows faster and easier surgery with all the advantages of a smaller incision. As an alternative the surgeon may use a three piece non foldable IOL. Only single piece foldable IOLs cannot be used since something firm is needed to be tucked into the sclera tunnel and then to be glued.

The trans-scleral fixation of the IOL per se makes it very stable with minimal pseudophacodonesis/endophthalmodonesis as compared to traditional suture fixated IOLs. Problems related to suture degradation, erosion, knot exposure, loosening of knot et cetera also do not occur with this technique.

The glued IOL technique has evolved over time. Since its inception, its use has been extended for many more indications. An aniridia IOL can be implanted using this technique. We

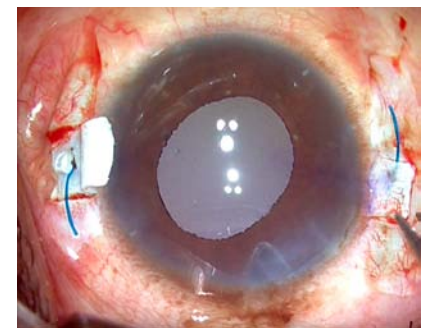

Figure 3: The "glued IOL" technique has become a rescue technique for many complicated cases.

have extended its use as a novel biosynthetic graft to simulate the anterior segment for Anterior Segment Transplantation (AST) in eyes with large anterior staphylomas. The procedure can be combined with either penetrating keratoplasty in aphakic bullous keratopathy cases or with endothelial keratoplasties. A dropped three piece IOL does not need to be explanted. It is possible to refixate the same IOL with the glued IOL technique.

The glue used is a quick-acting surgical fibrin glue sealant derived from human blood plasma (Tisseel, Baxter, USA), with both hemostatic and adhesive properties. Fibrin glue is composed of two separate solutions of fibrinogen or Factor 1 and thrombin. Fibrinogen is activated by thrombin to form fibrin monomers. Activated Factor XIII polymerizes fibrin monomers to form a stable fibrin clot, thus mimicking the last stages of the clotting cascade. Aprotinin delays fibrinolysis, the process that leads to the breakdown of blood clots. The commercially available fibrin glue that we used is virus inactivated and is checked for viral antigen and antibodies with polymerase chain reaction; hence the chances to transmit an infection are very low. ■

**Fr, 17 February 10.30 – 12.00 hrs**
**Hall 7**
**Session: IVI - Phaco nightmares and worst case scenarios**

**Author:** Prof. MD Amar Agarwal, MS, FRCS, FRCOphth
Dr. Agarwal's Eye Hospital
19 Cathedral Road
Chennai - 600 086, India
Tel: +91(0)44-2811-2811
Fax: +91(0)44-2811-5871
E-Mail: dragarwal@vsnl.com
www.dragarwal.com

# Excellent Medical Knowledge ever since

## Old Arabian Ophthalmology

THÜNGERSHEIM – Thinking of Arabia, many people in Europe or America think of oil, of big, modern buildings, of camels or of the desert. Only few of them will have Arabian medicine, especially ophthalmology in mind. But the world has to be most grateful to Arabia for its merits in medicine. For hundreds of years the medieval Europe benefited from Arabian medical knowledge and from Europe this knowledge spread all over the world.

Geographically Arabia can be defined as the area of northern Africa and the Arabian Peninsula. But in the Middle Ages the Arab world spread much further. The scientific medical works of the 8th up to the 13th century, published in Arabian language, covered an area from Spain in the west as far as Afghanistan in the east, and from the Caucasus in the north down to Central Africa in the south.

### Milestones in History

The Arabian medicine was strongly influenced by the Greeks, but as well by Egypt, Byzantium, Mesopotamia, Persia and India.

The earliest oculist known by name should be Iry in Egypt. He must have lived between 2723 and 2563 BC. His grave was found close to the pyramids of the kings Cheops, Chephren and Mykerinos. The inscriptions on his grave name him "the doctor of the pharaoh, guardian of the royal intestines-exit and oculist of the palace". So here we find a very early specialisation in medicine and just in ophthalmology, because Iry was mentioned as an oculist!

About 2000 BC we find a statement in the book of laws of Hammurabi about the therapy of eye-diseases in Babylonia and Assyria. The medical rules start with penalties for ophthalmological mistakes by oculists. This is a proof for the high standard of ophthalmology in this area and these times. The 20 m long "Papyrus Ebers" was written about 1550 BC and includes therapeutic suggestions for about 30 eye-diseases.

### Famous Names in Arabian Ophthalmology

Abu Zaid Hunain Ibn Ishaq Al-Ibadi (808–873), in Europe called "Johannitius", was the personal doctor of a caliph in Baghdad. He published different translations and compilations of Greek-Alexandrian medicine and the first textbook of ophthalmology in Arabian language "Kitab al-aschr maqalat fi al-ain" (Book of the Ten Treatisies of the Eye). The Arabian original script has been lost, but we know from Latin translations of 11 chapters:

1. Nature of the eye
2. Nature of the brain
3. Nervus optici and the view
4. Hygiene
5. Causes of eye diseases
6. Marks of eye-diseases
7. Effects of medicaments general
8. Eye-medicaments
9. Therapy of eye-diseases
10. Recipes

In some Latin prints an 11th chapter is added about ophthalmic surgery.

Abu Bekr Muhammad Ibn Zakariyya Al-Razi (850–923/932), in Europe called "Razes", was born in Raj/Persia. He studied Philosophy, Astronomy and Chemistry. He started his medical career at the age of 30 and became one of the important Arabian doctors. His compendium "Al-hawi" ("Continens" in Latin] was published after his death. He was the first to describe that pupils contract in the case of brightness and dilate by darkness.

Abul Qasim Khalaf Ibn Abbas Al-Zahrawi (910?–1013[!]?), in Europe known as "Abulkasim", published his work about surgery, "Al-tasrif", around the year 1000. It may be one of the earliest Arabian works about surgery and contains more than 200 illustrations about surgical, amongst them ophthalmological, instruments. For the treatment of an entropium he suggested cauterisation and burning. The developing scar should cause a correct position of the eyelid.

Abu Ali Al-Husaini Ibn Abdallah Ibn Sina (980–1037), "Avicenna", was born in the area of Buchara/Tajikistan. Like Razes he studied law, mathematics, astronomy and philosophy and then medicine. His work "Al-qanum fi altibb" (Guideline for the medical practise), also known as „Canon medicinae" was a true guideline. For 500 years this book was the leading book for medicine in Europe, beside the scripts of Galenos. Avicenna wrote about the whole medicine, including ophthalmology. He carried on research about the anatomy of the eyes and the therapy of eye diseases.

These examples not only prove the significance of the old Arabian ophthalmology, but also of the Arabian medicine in general and of all the other sciences. Why did this great knowledge have to be imported into Europe? One reason may be the fact that many Arabs could read and write at the time – unlike the majority of people in Europe. Literacy was encouraged by Mohammed, who demanded, that all the faithful have to improve their knowledge: "Search for knowledge from the cradle to the grave. Who is searching, prays to God!" ■

**Fr, 17 February 10.30 – 12.00 hrs**
**Capital Suite 7**
**Session: HIS - History of Ophthalmology 1**

**Author:** Frank Krogmann
Kirchgasse 6
97291 Thüngersheim, Germany
Tel: +49(0)9364-811543
Fax: +49(0)9364-811559
E-Mail: Frank.Krogmann@t-online.de

# Searching for the Best Treatment Strategy

## Is there still a Role for the Laser in the Treatment of Macular Edema?

LIMA - Diabetic macular edema is a leading cause of blindness among working people in the world. Laser treatment was the only effective treatment that we had two decades ago to prevent further loss of vision due to macular edema. Now we have intravitreal injections and some oral drugs that could help us dealing with this important cause of blindness.

We know that triamcinolone and anti-VEGF injections can effectively reduce macular thickness, and in some cases help to improve vision. But to have to inject an eye several times to achieve a steady result is neither desirable to the patient nor to the physician. That is why other forms of treatment with or without laser photocoagulation are currently under investigation.

Roca

José A. Roca

The Early Treatment Diabetic Retinopathy Study group (ETDRS) demonstrates that focal/grid laser photocoagulation reduced the risk of moderate loss of vision in patients with clinically significant macular edema (CSME) by 50% (from 24% to 12%) during the period of three years. On the other hand an improvement of the visual acuity (VA) was observed in less than 3% of cases, based on a gain of 15 letters after three years, 17% of the patients showed any improvement in vision. The characteristics of the participants in the ETDRS could limit the benefit obtained, because an important proportion of patients enrolled in the ETDRS had a basal VA of at least 20/40, so it was very difficult to reach an improvement of three lines. Among those participants that could improve three lines or more, 40% obtained it.

The Diabetic Retinopathy Clinical Research network (DRCRnet) compared intravitreal triamcinolone with the focal/grid laser treatment. Three years after the start of studies the group that had been treated with the laser had a mean improvement of five letters versus zero letters in the triamcinolone group. More patients in the triamcinolone group suffered from cataract and ocular hypertension than in the laser group.

In about 50% of the patients treated with laser the retinal central thickness remained unchanged. About 20% showed the worst visual acuity at the beginning of the study.

Anti-VEGF drugs (ranibizumab and bevacizumab) have demonstrated their effectiveness in reducing retinal central thickness and improving visual acuity in patients with macular edema secondary to diabetes. Investigators from the DRCRnet group conducted a study comparing ranibizumab with previous laser versus ranibizumab with differed laser. After one year follow-up in both groups the visual acuity improved compared to patients treated with laser alone. The difference between combined treatment (ranibizumab plus laser) versus laser treatment alone after one year amounted to nine letters. The results after two and three years of follow-up are necessary to estimate the real benefit of combined treatment. We still need to keep looking for the best strategy to deal with macular edema in order to maintain and to improve visual outcomes in diabetic patients: anti-VEGF injections followed by focal/grid laser photocoagulation, triamcinolone injection followed by focal/grid photocoagu-lation, or photocoagulation alone.

But the laser is, in these days, one of the most important tools that ophthalmologist have to control macular edema. ■

**Sat, 18 February 10.30 – 12.00 hrs**
**Hall 3**
**Session: RET - Macular edema**

**Author:** Dr. José A. Roca
Clinica Ricardo Palma
Av. Javier Prado Este 1066
San Isidro
Lima 27, Perú
Tel: +511(0)224-2224
+511(0)224-2226
E-Mail: jaroca62@yahoo.com

# A Giant Stride in Optimizing the Refractive Outcome

## Combining Multifocal and Toric IOLs

**AHMEDABAD – Many patients have a significant unilateral or bilateral astigmatism. To provide an optimal refractive outcome after cataract surgery multifocal IOLs alone are not enough.**

Vasavada (3)

Abhay Vasavada

Multifocal IOLs have steadily gained popularity among patients since they provide a greater degree of spectacle independence for activities at different distances following cataract surgery. However as has been reported, presence of astigmatism of 1D or more would significantly degrade the visual performance of a multifocal IOL. To manage the co-existent astigmatism, an additional intervention like LASIK or limbal relaxing incisions (LRI) would be required. But each procedure has its own limitation that is likely to make the outcome less predictable and satisfactory. In a survey of our own practice we found a high prevalence of significant corneal astigmatism (> 1D) similar to what has been reported in literature. We found that nearly 40% of our patients with cataract also had significant unilateral or bilateral corneal astigmatism and hence it was not possible to provide an optimal refractive outcome with multifocal IOL implantation alone.

### Customized Refractive Outcome

In other words, significant corneal astigmatism was perhaps the most common hurdle to multifocal IOL practice. The ideal solution would have been to combine the concept of multifocality and toricity in a single IOL. The new Multifocal Toric IOL has answered the need of the hour and promises to provide a customized refractive outcome by integrating the management of corneal astigmatism during cataract surgery itself. While the Multifocal Toric IOL offers to be a safe and effective option for those of our patients who are motivated to reach a greater degree of freedom from spectacles but have a significant astigmatism, the success of this IOL hugely depends on the platform that we provide for it. Hence, raising the bar of precision at every step of cataract management cannot be emphasized enough.

### Understanding Astigmatism

The due diligence at our end begins with the fundamental understanding of astigmatism and all its relevant components, like estimation of its magnitude and axis, choosing the appropriate type (regular astigmatism) and knowing our own surgically induced astigmatism. Since we are now aiming at a consistently predictable refractive outcome, our need for precision demands employing instrumentation that yields accurate estimation of the corneal astigmatism as well as a precise biometry evaluation. Ensuring negligible spherical equivalent, by using appropriate IOL calculation formula, is more important now than ever before.

The next step towards a successful outcome would be to ensure an optimal surgical result by using appropriate ophthalmic viscosurgical devices (OVDs) and an appropriate surgical technique. Appropriate size and centricity of the anterior capsulorhexis has become a requirement, in order to provide an adequate capsular 'wrap' all around the optic, which would help to maintain the effective lens position (ELP). Finally the precise placement of the toricity of the IOL on the intended axis, is of paramount importance (figure 1).

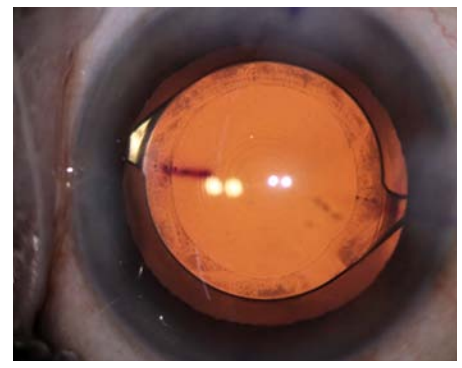

Figure 1: Intraoperative toric axis alignment of ReSTOR Toric IOL.



Figure 2: ReSTOR Toric IOL - 1 month postoperative.

Our experience of Multifocal Toric IOL implantation has been with the ReSTOR Toric IOL (Alcon Laboratories, Fort Worth, Texas). This single piece hydrophobic acrylic IOL has an aspheric apodized diffractive configuration on its anterior surface and toricity on its posterior surface. Of the 61 eyes (50 patients) that have received the ReSTOR Toric IOL in our practice, nearly as many patients had bilateral astigmatism as unilateral. The magnitude of astigmatism was in the range of 1 to 1.25D in 50% of the eyes. A significantly large number of patients, who opted for this IOL, had a moderate to high myopia. This gave us an insight into the preference pattern of our patients. It would seem that the myopes, who are blessed with good unaided near vision, are motivated to retain that ability even after cataract surgery. The postoperative visual performance, assessed at 1 month, was definitely encouraging. Unaided distance visual acuity was found to be 20/30 or more in 85% of the eyes. Unaided near visual acuity of N/8 or more, was seen in all the eyes with a fairly good reading range of 25 to 40cms. Residual refractive astigmatism was found to be 1D or less in all the eyes. Recently, Visser et al (JCRS, November 2011) have reported the visual outcomes following AT Lisa Toric IOL (n= 45 eyes), which is a plate haptic multifocal toric IOL. They have reported residual refractive astigmatism of 1D or less in approximately 90% of the eyes. In a questionnaire designed to find out if they could perform various routine activities at distance, intermediate and near, we found that all the 50 patients reported spectacle independence in their everyday life, following ReSTOR Toric IOL implantation.

### Attention to Detail

At this juncture, it would be fair to say that the ReSTOR Toric IOL offers a promising opportunity to optimize the refractive outcome in those patients who have cataract with significant corneal astigmatism. Incorporating this IOL into our practice would practically need no additional learning curve if one is familiar with multifocal and toric IOL implantation. Successful performance of this multifocal toric IOL largely hinges on our attention to detail and a diligent effort to ensure as much precision as is possible, at every step of cataract management. ■

**Fr, 17 February 10.30 – 12.00 hrs**
**Hall 10**
**Session: CAT - Astigmatism management at the time of cataract surgery**

**Authors:** Abhay Vasavada MD, FRCS (England), Lajja Shastri MD
Iladevi Cataract & IOL Research Centre
Raghudeep Eye Clinic,
Gurukul Road, Memnagar,
Ahmedabad - 380 052 India
Tel: +91(0)79-27492303, 27490909
Fax: +91(0)79-27411200
E-Mail: icirc@abhayvasavada.co

# Better Classification

**HOUSTON - Tumours of the lacrimal gland are rare but an important cause of ocular morbidity and cancer-related mortality.**

In this section the multi-disciplinary management of epithelial tumours of the lacrimal gland will be discussed with a view to better classification of tumours based on size and AJCC criteria. In addition, tumours of the lacrimal drainage apparatus and their multi-disciplinary management using globe preserving surgery followed by radiation therapy will be discussed through illustrative case presentations. ■

**Fr, 17 February 8.30 – 10.00 hrs**
**Conference Room A/B**
**Session: ONC – Orbital Tumors**

**Author:** Bita Esmaeli, MD, FACS
Professor of Ophthalmology
The University of Texas
M. D. Anderson Cancer Center
1515 Holcombe Blvd, Unit 1445
Houston, Texas 77030, USA
Tel: +1(0)713-792-4457
Fax: +1(0)713-794-4662
E-Mail: besmaeli@mdanderson.org

# Arabian Night

## The Cultural Event at the Emirates Palace



The venue for the cultural night: The Abu Dhabi Emirates Palace.

Kempinski

**ABU DHABI [jp] - The venue for the cultural night on 17 February reminds of the stories of the Arabian nights: The Abu Dhabi Emirates Palace, the biggest and most luxurious hotel in the world.**

Marble, gold and precious wood species remind of the big buildings of the golden age of the Orient. Located on 1.3 km of private beach the hotel is surrounded by 85 hectares of beautiful gardens. It has its own luxury shopping mall, a marina and a helipad. 2000 employes from 50 countries work at the Emirates Palace.

The building was designed by the renowned architect John Elliot RIBA. It is owned by the Abu Dhabi government and is managed by the Kempinski Group. The cost to build the hotel that opened in November 2005 were 11.02 billion AED (United Arab Emirates dirham, 1 AED = 0,2722 USD). The 114 domes are decorated with gold leaf. Many of the suites are furnished in gold and marble. The six Rulers' Suites in the topmost floor are reserved for Emirati royalty and dignitaries. ■

BIERMANN MEDIZIN

Publisher: Dr. Hans Biermann (bie)

Biermann Publishing Group
Otto-Hahn-Str. 7
D-50997 Köln
Germany
Tel: +49(0)2236-376-0
Fax: -999
Internet: www.biermann.net

Editor-in-Chief:
Dieter Kaulard (dk)
Tel: +49(0)2236-376-408
Fax: +49(0)2236-376-409
E-Mail: dk@biermann.net

Editorial Team:
Jeanette Prautzsch (jp)
Britta Achenbach (ac)

Managing Editor:
Michaela Schmid

Graphic Artist:
H. Udo Pößneck

Marketing:
Thijs van Egeraat
Tel: +49(0)2236-376-526
E-Mail: tve@biermann.net

# The End Game for Blinding Trachoma

## Where do we Stand as far as Global Elimination of Trachoma is Concerned, and how are we Going to Close the Gap?

**GEORGIA – Blinding trachoma, one of the oldest known infectious eye diseases, may be facing its end game.**

The world's leading cause of preventable blindness, trachoma, brings extraordinary human suffering and economic devastation to tens of millions of people, mostly women and children in poorer countries. Yet as a result of development and targeted interventions it is now limited to an estimated 59 countries, often affecting the poorest populations.

### New Global Strategic Plan

A new global strategic plan – 2020 INSight – created by an international coalition of partners, lays out specific actions to take and milestones to meet that could lead to elimination of blinding trachoma by the year 2020. At this year's World Ophthalmology Congress in Abu Dhabi, there is no better time to focus on what is needed to reach this ambitious goal: country leadership, international coordination, logistical and planning support, and adequate funding. Ophthalmologists around the world have a role to play.

Figure 1: 320 million people live in areas where they can be exposed to trachoma.

### 8 Million People Suffer from Trachomatous Trichiasis

An estimated 320 million people live in areas where they can be exposed to trachoma, a Neglected Tropical Disease (NTD). Repeated infections with Chlamydia trachomatis of the conjuctivae and scarring lead to inturned eyelashes, entropion causing trichiasis. This extremely painful condition ultimately leads to corneal opacity and blindness.

Trachoma blinds one person every 15 minutes and makes one person experience severe sight loss every four minutes. Over 8 million people are suffering from trachomatous trichiasis (TT) the final, painful stage of this eye disease and require surgical lid rotation to prevent them from going blind. However, studies have shown high levels of recurrence after trichiasis surgery. Reasons for this are poor technique and quality of surgery. With a major backlog of TT surgeries even after prevention and treatment targets have been met, ophthalmologists could play a critical role in this area by providing training and supervision for those performing TT surgeries.

### SAFE Strategy

Our goal to eliminate blinding trachoma in less than nine years is, indeed, ambitious, but it is also achievable. The primary reason for hope is the World Health Organization (WHO)-endorsed SAFE strategy. SAFE brings Surgery, Antibiotics, Facial cleanliness and Environmental improvement to the poorest communities where trachoma is most likely to be found. To implement SAFE, national governments and non-governmental organizations around the world are uniting like never before.

Figure 2: More than 8 million people suffer from trachomatous trichiasis and require surgical lid rotation to prevent them from going blind.

Figure 3: Facial cleanliness is one of the main aspects of the SAFE strategy.

Over the last year, the International Trachoma Initiative worked with fellow partners in the International Coalition of Trachoma Control (ICTC) to create the global strategic plan 2020 INSight. The plan takes a hard look at where we are now, where we want to go over the next nine years, how we get there, and the cost and impact of finally eliminating blinding trachoma.

Mapping and assessing the magnitude of the disease is critical to defining areas that are priority for implementation of trachoma control efforts. About 1,115 districts in endemic countries have been surveyed in the last 12 years, but data must be gathered in at least 1,293 more districts to complete the picture. Out of the surveyed districts, 559 are endemic for trachoma and require implementation of the SAFE strategy. The total population in these areas is 110 million, and another 210 million live in districts where trachoma is suspected but no data are available to guide public health interventions and where surveys are urgently needed.

Figure 4: Four elements constitute the SAFE strategy.

Figure 5: A dollar spent on trachoma control is not only well spent but yields personal and economic benefits to individuals, communities, and countries.

All photos courtesy of ITI

### Immediate Action Needed in 14 Countries

The good news is that nine countries with trachoma have already reported achieving elimination targets. More than 80 percent of the burden of active trachoma is now concentrated in 14 countries, where immediate action is needed. Scaling up public health interventions described in the SAFE strategy, including antibiotic treatment with Zithromax®, which is generously donated by Pfizer Inc, and improved access to water and sanitation, are the most crucial elements in the fight to stem transmission. Trachoma control programs must be underway by 2015 in affected countries to be sure that there is enough time to eliminate the disease by 2020.

2020 INSight lays out five guiding principles that provide a framework for making progress on the path to elimination: urgency for action and scale-up; accountable ownership by countries so they can integrate actions into the national health services; integration so that trachoma focused efforts are aligned with activities for other NTDs, eye care and development strategies; efficient, coordinated partnerships with all stakeholders; and tailored interventions to meet local needs and context.

### Benefits at the Human and Economic Level

Delayed action will be costly. There is the human cost that occurs when vision loss or worse, blindness, leads to loss of social status, stigmatization and reclusion from society. There is the economic burden of trachoma on the lives of individuals, families, and communities that is enormous. Even conservative estimates suggest an annual loss of productivity due to trachoma between $3 billion and $6 billion. Eliminating blinding trachoma will clearly bring benefits at the human and economic level. What will it cost to achieve that elimination goal?

2020 INSight calculates that an estimated $748 million in funding is needed to fully implement the SAFE strategy to prevent and treat blinding trachoma. Eliminating the disease in Africa alone would boost the continent's GDP 20-30 percentage points based on conservative annual productivity loss estimates. A dollar spent on trachoma control is not only well spent but yields personal and economic benefits to individuals, communities, and countries. As 2020 INSight states, "The total cost is relatively small, the potential for impact enormous."

### One of Five Priority Diseases for VISION 2020

Those of us involved in the fight against trachoma are hopeful. Trachoma was named as one of five priority diseases for the VISION 2020 "The Right to Sight" global initiative for the elimination of avoidable blindness launched by WHO and the International Agency for the Prevention of Blindness back in 1999. There has been much great news to report over the past 12 years. If the global community uses our new strategic plan to focus time, attention and funding, trachoma doesn't stand a chance.

We hope that those of you gathered for this year's World Ophthalmology Congress in Abu Dhabi will join us in this fight to end blinding trachoma. We invite you to contact us to learn more about the need for training and supervision for TT surgeries and about the part you can play. ■

**Fr, 17 February 10.30 – 12.00 hrs**
**Conference Room B/C**
**Session: WFS - Can trachoma be eliminated in the next decade: what are the challenges?**

**Author:** Dr. Danny Haddad
Director
International Trachoma Initiative
325 Swanton Way
Decatur, Georgia 30030, USA
E-Mail: dhaddad@taskforce.org
www.trachoma.org

### References:

1. 20220 INSight can be found at http://www.trachomacoalition.org/node/713
2. Rajak SN, Makalo P, Sillah A et al. Trichiasis surgery in the Gambia: a 4-year prospective study. Invest Ophthalmol Vis Sci 2010;510:4496–5001.

# Water-Drinking Test

## Revival of an Abandoned Diagnostic Tool

SÃO PAULO – The water-drinking test is helpful to assess the IOP profile of glaucomatous patients.

Susanna

Remo Susanna Jr.

The water-drinking test was first described by Schmidt as a diagnostic tool for glaucoma[1]. However, it was later abandoned due to its poor diagnostic accuracy[2,3].

### Growing Interest

Recently this test was revived with a new purpose. Studies have shown that the water-drinking test may be used as a surrogate for detecting patients who have IOP spikes not identified during office hours.[4,5] The water-drinking test has also been used to evaluate the effect of treatment on reducing IOP peak and fluctuation, both with ocular hypotensive medications and filtering surgery[6-13]. Also, the peak of the water-drinking test correlates with the severity of glaucoma[14] and a patients' response to the water-drinking test may be predictive of visual field progression[15-17].

There has been a growing interest in the water-drinking test among ophthalmologists. This test has been cited a mean of 10.26 times in the literature[18] and has been the title of three editorials in peer-review journals[18-20].

It has been used to assess the quality of treatment, and how a given eye is able to control its IOP. Also, the IOP peaks of the water drinking-test strongly correlate and are in agreement with IOP peaks that normally occur during the day.

This lecture will show the importance of this test to assess the IOP profile of glaucomatous patients and how it can be used to make therapeutic decisions. ■

**Thu, 16 February 13.00 – 14.30 hrs**
**Hall 11**
**Session: GLA - Intermediate**

**Author:** Remo Susanna Jr. MD
Professor and head
Department of Ophthalmology
University of São Paulo
Av. São Gualter, 99
05455-000 São Paulo SP - Brazil
Tel: +55(0)11-3022-2738
Fax: +55(0)11-3022-4300
E-Mail: rsusanna@terra.com.br

## References

1. Schmidt K. Untersuchungen über Kapillarendothelstörungen bei Glaukoma simplex. Arch Augenheilkd 1928;98:569-581.
2. Roth JA. Inadequate diagnostic value of the water-drinking test. Brit J Ophthalmol 1974;58:(1)55-61.
3. Rasmussen KE, Jorgensen HA. Diagnostic value of the water drinking test in early detection of simple glaucoma. Acta Ophthalmol 1967;54(2):160-164.
4. Miller D. The relationship between diurnal tension variation and the water-drinking test. AJO 1964;58:243-247.
5. Susanna R, Medeiros FA, Vessani RM. Correlation between intraocular pressure peaks in the diurnal tension curve and in the water-drinking test [ARVO Abstract]. Invest Ophthalmol Vis Sci 2001;42:S558. Abstract nr.2995.
6. Susanna R Jr, Medeiros FA, Vessani RM et al. Intraocular pressure fluctuations in response to the water-drinking provocative test in patients using latanoprost versus unoprostone. J Ocul Pharmacol Ther 2004;20(5):401-410.
7. Christiansen GA et al. Mechanism of ocular hypotensive action of bimatoprost (Lumigan) in patients with ocular hypertension or glaucoma. Ophthalmology 2004;111(9):1658-1662.
8. Susanna R Jr, Sheu WP; Latin American Glaucoma Society. Comparison of latanoprost with fixed-combination dorzolamide and timolol in adult patients with elevated intraocular pressure: an eight-week, randomized, open-label, parallel-group, multicenter study in Latin America. Clin Ther 2004;26(5):755-768
9. Facio AC, Reis AS, Vidal KS et al. A comparison of bimatoprost 0.03% versus the fixed-combination of latanoprost 0.005% and timolol 0.5% in adult patients with elevated intraocular pressure: an eight-week, randomized, open-label trial. J Ocul Pharmacol Ther 2009;25(5):447-451.
10. Hatanaka M et al. Additive intraocular pressure reduction effect of fixed combination of maleate timolol 0.5%/dorzolamide 2% (Cosopt) on monotherapy with latanoprost (Xalatan) in patients with elevated intraocular pressure: a prospective, 4-week, open-label, randomized, controlled clinical trial. J Glaucoma 2010;19(5):331-335.
11. Hatanaka M, Grigera DE, Barbosa WL et al. An eight-week, multicentric, randomized, interventional, open-label, phase 4, parallel comparison of the efficacy and tolerability of the fixed combination of timolol maleate 0.5%/brimonidine tartrate 0.2% versus fixed combination of timolol maleate 0.5%/dorzolamide 2% in patients with elevated intraocular pressure. J Glaucoma 2008;17(8):674-679.
12. Medeiros FA et al. Intraocular pressure fluctuations in medical versus surgically treated glaucomatous patients. J Ocul Pharmacol Ther 2002;18(6):489-498.
13. Chen CH, Lu DW, et al. The application of water drinking test on the evaluation of trabeculectomy patency. J Ocul Pharmacol Ther 2000;16(1):37-42.
14. Susanna R Jr, et al. Correlation of asymmetric glaucomatous visual field damage and water-drinking test response. Invest Ophthalmol Vis Sci 2006;47(2):641-644.
15. Yoshikawa K, Inohue T, Inohue Y. Normal tension glaucoma: The value of predictive tests. Acta Ophthalmol 1993;71(4):463-470.
16. Armaly MF, Krueger DE, Maunder L et al. Biostatistical analysis of the Collaborative Glaucoma Study. I. Summary report of the risk factors for glaucomatous visual-field defects. Arch Ophthalmol 1980;98(12):2163-2171
17. Susanna R Jr et al. The relation between intraocular pressure peak in the water drinking test and visual field progression in glaucoma. Br J Ophthalmol 2005;89(10):1298-1301
18. Fan JC et al. Publication and citation in ophthalmology: glaucoma and the water provocation test – wring out the old and ring in the new? Clin Exp Ophthalmol 2008;36(4):304-305.
19. Danesh-Meyer HV. The water-drinking test: the elegance of simplicity. Clin Exp Ophthalmol 2008;36(4):301-303.
20. Goldberg I, Clement CI. The water drinking test. AJO 2010;150(4):447-449.

# Rapidly Evolving Field

## New Therapies for Wet AMD

KARLSRUHE – The treatment of wet age-related macular degeneration (AMD) is the most rapidly evolving field in ophthalmology. Laser treatment was replaced by photodynamic therapy (PDT) which was able to reduce the vision loss significantly. Today we are already able to increase vision in wet AMD-patients either by using ranibizumab/bevacizumab or VEGF-Trap.

In addition, there are numerous treatments under investigation. Those approaches can be grouped according to the therapeutic target:

### 1. VEGF Cascade

Multiple molecular interactions finally result in the production of vascular endothelial growth factor (VEGF). A key step in the VEGF production involves a molecule known as mTOR (mammalian Target of Rapamycin), a protein kinase that regulates cell proliferation, motility, survival and protein synthesis. It leads to the activation of certain transcription factors, including hypoxia-inducible factor 1α (HIF1α), which activates several genes, including those that produce VEGF.

RTP801 (REDD1) is a gene that displays strong hypoxia-dependent upregulation in ischemic cells of neuronal origin. It promotes VEGF production through the mTOR/HIF1α pathway. RTP801i-14 (Quark/Pfizer), now known as PF-4523665, is a small interfering RNA (siRNA) that has been developed to inhibit REDD1 and suppress VEGF production as well as inhibit angiogenesis.

The signaling pathways are addressed by mTOR-inhibiton (Sirolimus (Rapamycin); Everolimus (RAD001); Palomid 529).

Sirolimus (Rapamycin) exhibits significant antitumor/antiangiogenic activity that is coupled with a decrease in vascular endothelial growth factor (VEGF) production and a reduction in the response of vascular endothelial cells to stimulation by VEGF.

Everolimus (RAD-001) is the 40-O-(2-hydroxyethyl) derivate of Sirolimus and works similarly to sirolimus as an mTOR (mammalian target of rapamycin) inhibitor. It is currently used as an immunosupressant to prevent rejection of organ transplants and treatment of renal cell cancer. Much research has also been conducted on Everolimus and other mTOR inhibitors for use in different cancers.

Palomid 529 (P529) is a novel potent antitumour PI3K/Akt/mTOR inhibitor. Palomid 529 (P529) inhibits the TORC1 and TORC2 complexes and shows both, inhibition of Akt signaling and mTOR signaling similarly in tumor and vasculature.

Palomid 529 (P529) inhibits tumor growth, angiogenesis, and vascular permeability. It has been shown that Palomid 529 (P529) inhibited both, VEGF-driven (IC50 = 20 nM) and bFGF-driven (IC50 = 30 nM) endothelial cell proliferation and retained the ability to induce endothelial cell apoptosis.

### 2. VEGF and VEGF-Receptor

Once VEGF is generated therapeutic agents which directly target the VEGF molecule (ranibizumab/bevacizumab or VEGF-Trap) are used. This is the most advanced approach.

Augustin

Albert J. Augustin

More anti-VEGF molecules such as KH902 are currently under investigation. KH902 is a fully human fusion protein containing key domains from vascular endothelial growth factor receptors 1 and 2 with human immunoglobulin Fc.

Furthermore, there are several approaches under investigation to target the VEGF-receptor directly and/or integrins in general.

### 3. VEGF Effects

Following production VEGF binds to its receptors. By doing so the molecule initiates a series of events which are mediated by tyrosine kinase (tk). Thus, tk-inhibitors should be also efficient in counteraction VEGF-initiated effects in the tissue.

Currently the kinase inhibitors pazopanib and AL39324 are under investigation. So far the following clinical data is being generated for pazopanib in ophthalmology: A 28 day phase II study to evaluate the pharmacodynamic effect of pazopanib eye drops on the central retinal thickness of AMD patients has been performed. Currently, a phase IIb dose-ranging study is underway to investigate the efficacy of pazopanib eye drops in patients who are being treated with ranibizumab injections.

Additionally, a 12 week, open-label phase II study to investigate the safety and efficacy of a single dose regimen of pazopanib eye drops for neovascular age-related macular degeneration is being carried out.

### 4. Additional Pathways in the Angiogenic Cascade

Besides the VEGF-cascade tubulin-inhibition (Combretastatin, fosbretabulin, OX-10X), acting against sphingosine-1-phosphate (S1P) with potential antiangiogenic and antineoplastic activities (sonepcizumab), inhibition of pigment epithelium derived factor (Ad-PEDF) or Platelet-derived growth factor (PDGF; E1030) and complement inhibition (POT-4 (AL-78898A) are further promising therapeutic attempts.

Microtubules, a major type of cytoskeletal filament in cells, are formed from tubulin subunits, including α-tubulin and β-tubulin. They play an important role in cellular functions, such as replication, cell movement and organelle transport. Thus, antagonization of those molecules should exert an antiangiogenic effect.

Sphingosine-1-phosphate (S1P) is a bioactive lipid molecule that stimulates endothelial cell migration, proliferation, and survival in vitro, and tumor angiogenesis in vivo. Again, targeting this molecule should reduce proliferative activity.

POT-4 (Potentia Pharmaceuticals, Inc.), a small molecule derivative of Compstatin is directed against complement factor C3. POT-4 is a cyclic 13 amino acid peptide, which interferes with the cleavage of C3, the component all 3 pathways of complement activation converge on. It is the first complement inhibitor studied in patients with AMD. POT-4 has completed phase 1 testing in patients with wet AMD with an excellent safety profile. A unique feature of POT-4 is that it persists as a long-lasting gel deposit after intravitreal injection. The study demonstrated that significant levels of drug are maintained in the vitreous cavity for up to 6 months following a single injection. A phase 2 study is currently under way.

Genentech/Roche is working on anti-factor D (FCFD4514S) that inhibits the C3 and C5 alternative pathway convertases. Phase 1 studies have been successfully completed.

Furthermore, two C5 inhibitors are being studied: Eculizumab/Sollris (Alexion) and ARC1905, an anti-C5 aptamer (Ophthotech).

In summary, the inflammatory cascade plays a significant role in this disease entity. Therefore, targeting this part of the pathway could be a very effective approach in the future of wet AMD treatments.

### 5. Vitreoretinal Traction

This part of the disease entity has been underestimated so far. The elimination of vitreoretinal traction by means of surgery or with a vitreolytic agent therefore can be reasonable when traction contributes significantly to the disease process. In those subjects who are not responding adequately to anti-VEGF the vitreous body should be investigated in detail. A prospective trial to investigate this approach is pending. ■

**Fr 17 February 13.30 – 15.00 hrs**
**Capital Suite 13**
**Session: PHA - Drugs for posterior segment disease**

**Author:** Prof. Dr. Albert J. Augustin
Städtische Klinikum Karlsruhe
Moltkestr. 90
76133 Karlsruhe
Germany
Tel: +49(0)721-974-2010
Fax: +49(0)721-974-2009
E-Mail: albertjaugustin@googlemail.com

# A Promising Innovation for Complicated Cases

## Experience with the VICTUS Femtosecond Laser Cataract Surgery Procedure

**HEIDELBERG – Early experience with a new femtosecond laser platform prove to be promising and safe for the use in patients with pre-existing conditions such as black/brown cataracts or pseudoexfoliation syndrome.**

Auffarth (3)

Gerd U. Auffarth

The new VICTUS femtosecond laser platform (Bausch + Lomb/Technolas Perfect Vision) is a versatile system which provides refractive, therapeutic and cataract applications. The laser features real-time OCT and also employs a curved patient interface, which is used in combination with the intelligent pressure sensors to minimise corneal applanation and corneal folds. CE Mark approval for the femtosecond laser platform was recently obtained in early December 2011.

Initially laboratory studies on pig and human cadaver eyes were conducted at the University of Heidelberg. These studies measured the maximum applicable stretch force of the capsular bag, following anterior capsulotomy with either the femto-second laser or with the manual technique in freshly enucleated eyes. Results for the capsular bag stretch force required to rupture it found that 113±12 micro Newtons (mN) of force were necessary to rupture the capsular bag in the femtosecond laser group compared to 73±22 micro Newtons (mN) in the manual capsulotomy group. This difference was statistically significant. Stretching ratio measurements were also calculated, where the stretching ratio is defined as the circumference of the donut-shaped anterior capsula immediately before rupture divided by the unstretched diameter - i.e. 5 mm. Results found a higher stretching ratio using the femtosecond laser procedure of 1.67±0.08, compared to 1.36±0.05 using the manual technique.

In the clinical setting, a preliminary evaluation of the femtosecond laser cataract surgery procedure on the VICTUS platform at Heidelberg University assessed the safety and efficacy of performing the anterior capsulotomy and lens fragmentation in cataract patients with pre-existing conditions. Patients with pre-existing conditions such as black/brown cataracts, pseudoexfoliation syndrome (PEX), amblyopia or zonular atrophy were selected to undergo the femtosecond laser cataract surgery procedure in this single surgeon, single centre evaluation. Following anterior capsulotomy and lens fragmentation using the VICTUS femtosecond laser platform, phacoemulsification and intraocular lens implantation has been performed using standard manual techniques. Measured outcomes included safety, efficacy, precision and centration of the capsulotomy, use of different lens fragmentation patterns and ease of use of this new femtosecond laser procedure.

To date, 9 eyes (8 patients) have undergone the femtosecond laser cataract procedure. The procedure has been safely performed in all cases, providing good visual outcomes. Docking of the curved interface is straightforward and the graphic user interface (Figure) incorporating the OCT allows easy procedural planning as well as monitoring. The anterior capsulotomies created have been well centred and accurate.

The first patient to undergo a femtosecond laser anterior capsulotomy in Germany was a 66 year old female patient with a black cataract (OS) and PEX, in May 2011. The surgery was uneventful. Pre-operatively, the patient could only see hand movements, had UDVA of 0.02 and CDVA of -5.0/0/0 = 0.05. At 3 weeks post-operatively, the patients visual acuity had improved to an UDVA (OS) of 0.8 and CDVA of 0/-0.75/180 = 1.0.

Lens fragmentation has been performed on all cataract grades. Different lens fragmentation patterns such as radial cuts, ring cuts or combinations of both have been applied.

In our first case where both the anterior capsulotomy and the lens fragmentation were carried out with femtosecond cataract surgery, a 65 year old male presented with cortico-nuclear cataracts (OU) and amblyopia (OS). With the first eye (OS), the procedure was performed under general anaesthetic, whilst the procedure was performed under topical anaesthesia with the fellow eye (OD). A cross pattern/radial cuts were applied for lens fragmentation. The bilateral implantation of posterior chamber toric IOLs occurred without complications. The patients visual acuity improved from pre-operative CDVA OD +1.25/-1.25/177 = 0.5 and CDVA OS of +4.75 = 0.25 to postoperative UDVA OD of 0.8 and UDVA OS 0.32.

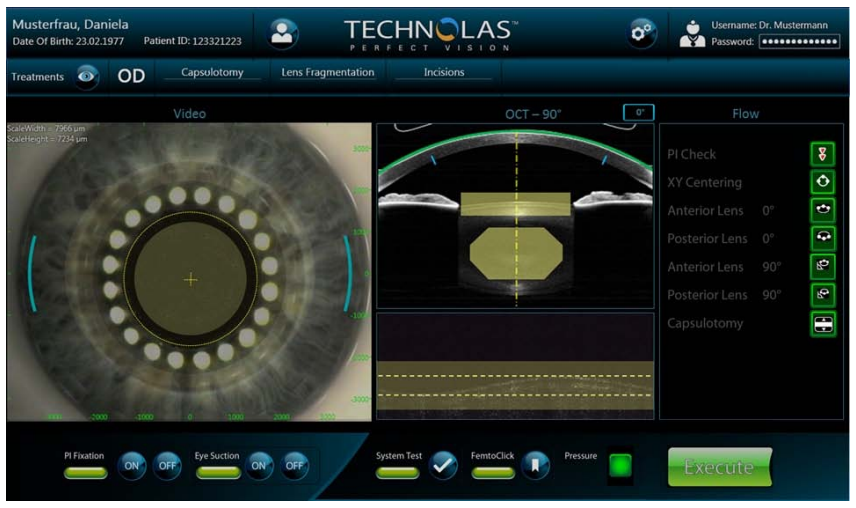

The graphic user interface allows easy planning and monitoring.

In summary, early experience using the femtosecond laser cataract surgery technique indicates it is a very promising procedure which can be safely and effectively used in patients with pre-existing conditions. Further evaluations are on-going to obtain further data on visual outcomes, use of different lens fragmentation patterns and the incorporation of this technique into routine practice. ■

**Sat, 18 February 13.30 – 15.00 hrs**
**Hall 10**

**Session: ISREF - Emerging Techniques in Refractive Surgery**

**Author:** Prof. Dr. Gerd U. Auffarth
Dept. of Ophthalmology, Univ. of Heidelberg
Im Neuenheimer Feld 400
69120 Heidelberg, Germany
E-Mail: Gerd_Auffarth@med.uni-heidelberg.de

# Targeting High-Risk Groups

## What is the Most Cost-Effective Screening Method for Glaucoma in Areas of Limited Resources?

**BEJING – The World Health Organization ranks glaucoma as the second most common cause of blindness after cataract, and the most common cause of irreversible blindness globally.**

The World Health Organization recommends the criteria which should be fulfilled before any population based screening is undertaken.

1. The disease must be an important public health problem.
2. There must be a recognizable latent or early stage, during which persons with the disease can be identified before symptoms develop.
3. There must be an appropriate, acceptable and reasonably accurate screening test.
4. There must be an accepted and effective treatment for patients with the disease that must be more effective at preventing morbidity when initiated in the early asymptomatic stage than when begun in the later, symptomatic stages of the disease.
5. The cost of case finding must be economically balanced in relation to possible expenditure on medical care as a whole.

It is estimated that the number of people affected by primary angle closure glaucoma (PACG) and primary open angle glaucoma (POAG) in China will be approximately 47.5% and 18.6% respectively of the whole popu-lation of glaucoma in 2010. China has the heaviest burden of glaucoma. Glaucoma has been an important public health problem in China. However, deciding to screen for glaucoma is a process that requires careful considering of both the benefits of early disease detection and intervention and the cost of case finding.

Wan

Ningli Wang

The cost-effective studies of POAG screening give us more indications. The study of Boivin et al. indicated that the initial scenario comprised three-yearly POAG screening of subjects aged 40-79. The assumption of levels of participation in screening and of compliance with treatment of 75%, and treatment efficacy of 50% resulted in a cost of $C100,000 per year of blindness prevented. A scenario in which screening was restricted to subjects aged 65-79, with the same input variables, would prevent 81% of the cases of blindness prevented with scenario 1, at a cost of $C42,000 per year of blindness prevented. Screening in the elder population was more cost-effective. Tuck and Crick compared various modes of screening for glaucoma. The best balance between sensitivity (> or = 80%) and cost per true positive was found on all glaucoma high-risk groups. Hitzl et al. aimed to report costs, detection rates, and resources needed for detection of primary open angle glaucoma and related diseases in a glaucoma screening programme in Salzburg, Austria, over a period of 8 years. Direct costs per visit were considerably higher than those reported in the Netherlands or the United Kingdom. If a health care provider decides to perform a glaucoma screening within this setting, the costs for the detection of a new case are EUR 7250 for definite POAG, EUR 4250 for early POAG, EUR 1450 for POAG suspect, EUR 5600 for OHT, EUR 2100 for glaucoma artefact case, and EUR 156 for a normal case. The similar studies revealed a trend: screening should be carried out in high risk populations.

We can also use some models to show the trend. First, several definitions should be clarified. Screening usually means population-based screening, which is population-based detection of disease or pre-disease states. Case Detection, also called opportunistic screening, is the active detection of disease or pre-disease states when patients visit clinics and hospitals. Prevalence of a condition means the proportion of patients with the target disease or pre-disease state in the population tested. Sensitivity is the ability of a test to correctly identify those true positives who have the disease or its precursor conditions. Specificity is the ability of a test to correctly identify those true negatives or normal persons who do not have the disease or its precursor states. Positive Predictive Value (PPV) of a test is the proportion of patients with positive results who in truth have the condition for which one is screening.

We presume three populations with different prevalence of glaucoma, 0.5% (aged 20 years old or above), 5% (aged 40 years old or above), and 20% (glaucoma patients' siblings). When the Sensitivity and the Specificity were kept equal (80% and 80% respectively) in all three populations, the PPV was increased into 1.97%, 17.39%, and 50% respectively.

In order to increase the PPV of a screening test, a higher prevalence of disease is desirable. So, we can "increase" the presumed prevalence of glaucoma and precursor states by targeting high-risk groups such as the elderly, persons with family history of glaucoma. ■

### Reference:

1. Quigley HA, Broman AT. The number of people with glaucoma worldwide in 2010 and 2020. Br J Ophthalmol 2006;90(3):262-267.
2. Boivin JF, McGregor M, Archer C. Cost effectiveness of screening for primary open angle glaucoma. J Med Screen. 1996;3(3):154-163.
3. Tuck MW, Crick RP. The cost-effectiveness of various modes of screening for primary open angle glaucoma. Ophthalmic Epidemiol 1997;4(1):3-17.
4. Hitzl W, Ortner C, Hornykewycz K et al. Resource use and costs for a glaucoma screening program in Austria: an 8-year review: a cost-consequence analysis based on the Salzburg-Moorfields Collaborative Glaucoma Study. Eur J Ophthalmol 2006;16(1):92-99.
5. Thomas R, Parikh R, Paul P, et al. Population-based screening versus case detection. Indian J Ophthalmol 2002;50(3):233-237.

**Fr, 17 February 13.30 – 15.00 hrs**
**Conference Room B/C**

**Session: WFS - Public health control strategies for glaucoma: what are the prospects?**

**Author:** Ningli Wang
Beijing Tongren Eye Center, Beijing Tongren Hospital, Capital Medical University, Beijing Ophthalmology and Visual Sciences Key Laboratory, Beijing, China
E-Mail: wningli@vip.163.com

# The Experience of Jordan Eye Bank

## Successful Donation Programmes Count on the Help of Religious Leaders

AMMAN - Jordan Eye Bank (JEB) was established in 1979, as a national, non-profit institution devoted to the restoration of sight. It is based at Jordan University Hospital in Amman and funded by 4 sectors: Ministry of Health, The University of Jordan, Royal Medical Services and Jordan University of Science and Technology. It is run by a committee of five ophthalmologists representing those sectors as well as the private sector.

The main Goals and Objectives of JEB are:

- to organize and provide basic structure for corneal transplantation in Jordan,
- to spread the awareness of the importance and need for local corneal donation and
- to provide corneas for patients in need via local donation or importation from international eye banks suppliers.

JEB supplies trephines, solution to preserve corneas free of charge to all public hospitals and provides corneal graft surgical sets almost every other year to four major hospitals. In Jordan the number of patients in need for corneal grafting is about 1,300 patients in all health sectors.

It is worth mentioning here that Jordan is a small developing country with a population size of about six million. In Jordan, 94% of the people are Moslems and 6% are Christians that live in peace together. With regards to local corneal donation, we stress that the religious point of view is an important issue in our society. Successful donation programmes should include identification and engagement of key religious leaders in the community to proactively support and promote the option of donation.

Islam and Christianity support organ and tissue donation as one of the highest expressions of compassion and generosity. The General Iftaa Department of the Ministry of Awqaf and Religious Affairs has issued a Fatwa on 22 June 1988 permitting partial or complete donation of human organs, including corneas, after death conditional to the donors tacit and voluntary approval in their lifetime. As for after death, the principles of Islamic Shari'a permit benefiting from organs of dead bodies under the following conditions:

> **"It's not how much we give but how much love we put into giving." (Mother Teresa)**

1. Verifying the donor's death.
2. Donor's explicit approval during his lifetime to donate the organs mentioned, or to donate one of them voluntarily and at his own will, or the approval of his kin according to inheritance hierarchy if his identity is known and his family and relatives are known.
3. A high likelihood of success of the transplant operation based on the opinion of specialized physicians.
4. Total inability of treatment in the absence of organ transplant.


Bdour
Muawyah Al Bdour

From 1979 till 1991 we were not able to extract local corneas. From 1992 till the end of 2011, more than 2800 local corneal transplants were performed in Jordan according to JEB records. We attribute this to the clear statement in 1988 by the religious authorities permitting corneal donation.

From 1992 till 2006 the average number of local donation was 95 corneas/year. The average of local donation became 285 corneas/year over the past five years. This was achieved with the help of different institutions, the media, JEB Friend Society and campaigns held by local radio stations.

JEB started implementing its new role since 1 August 2003 by importing corneas for all the health sectors in Jordan. In order to control the quality and cost of imported corneas, the Cabinet made a decision allowing only Jordan Eye Bank to import corneas, along with controlling the quality of local donation. The imported corneas exclusively come from: Tissue Banks International (TBI), North Carolina Eye Banks, Heartland Lions Eye Banks, International Sight Registration (ISR) and Midwest Eye Banks. The recipient has to pay for the shipment and cost of tests ran on the imported corneas, on the other hand, local corneas are provided to recipients free of charge.

Cornea importation has decreased. As an example; here are some figures for the years and number of corneas imported:

2005: 440 corneas
2007: 378 corneas
2008: 285 corneas
2010: 276 corneas
2011: 221 corneas

This decrease in importation goes back to the fact that we have been extracting more local corneas and we had a large number of keratoconus patients whom we could recently treat with intrastromal corneal rings instead of corneal grafting.

### JEB – a Look into the Future,

In order to be accepted as a member of the International Federation of Eye Banks, JEB is moving few steps towards its target, such as: setting new regulations under the umbrella of Ministry Of Health, having specular microscope and corneal topographer (Pentacam HR), appointing and training staff and interchanging experience. JEB had a good experience with Midwest Eye Banks which has brought great benefits. During 2011, two short visits by an active team from Midwest Eye Banks were made to JEB to explore its current situation and to give advice on eye banking. The visits were very fruitful. Midwest Eye Banks thankfully donated a new specular microscope and provided the required training to our bank technicians. A mutual agreement was signed to revise JEB polices and its medical standards and to provide JEB a technical support in order to make it a model in the area.

### Conclusion

As a conclusion, JEB with all the efforts made by people with a vision of how the world could be a better place has crossed a long way to becoming one of the most important Eye Banks in the Middle East.

Needless to say, that with the help of donors, we will keep making a difference and giving hope to all in need.

Two things about eye banking do remain the same: the smile recipients have when their sight is restored and their gratitude to the generous donors who made it possible. ■

**Fr, 17 February 15.30 – 17.00 hrs**
**Hall 1**
**Session: COR - Eye banking**

**Author:** Muawyah Al Bdour
Director, Jordan Eye Bank
E-Mail: bdourjo@yahoo.com

# Most Useful for Non-Invasive Examinations

## Corneal Imaging using Three-Dimensional Anterior Segment OCT

OSAKA - The OCT technology will play an increasingly important role as non-invasive and quantitative modality for examining the anterior segment of the eye.

Maeda (3)
Naoyuki Maeda, MD

Since optical coherence tomography (OCT) was introduced as a non-contact imaging method that provides detailed cross-sectional images of internal structures of the tissues[1], OCT has been attracting a great deal of attention in the field of Ophthalmology. It caused a paradigm shift in diagnosing and treating retinal diseases.

The first report of OCT imaging of the cornea and the anterior segment of the eye was published in 1994[2]. The time-domain OCT at 1,310 nm (Visante, Carl Zeiss Meditec, Inc., Dublin, CA) has become commercially available for cross-sectional images of the cornea, anatomic structures of the iridocorneal angle, and anterior chamber biometry. The anterior segment of the eye can be visualized and quantified non-invasively in the clinic. Anterior segment OCT (AS-OCT) is now frequently used not only for diagnosing the pathology of the anterior segment, but also for planning and evaluating anterior segment surgery such as DSAEK and DALK. The resolution in vertical direction is 18 µm and the speed of the A-scan is 2000 scans per second with the 1,310 nm time-domain OCT.

On the other hand, higher resolution (5 µm) and faster speed of the A-scan (26000 scans per second) can be obtained with the 840 nm spectral-domain OCT (RTVue-100, Optovue Inc., Fremont, CA). Bowman's layer can be identified as the parallel lines, and the thickness profile of epithelial layer and stromal layer of the cornea can be analyzed separately with SD-OCT, although it is difficult to obtain images clear enough to separate the epithelial layer from the stroma in a normal cornea with TD-OCT. The details of bullous keratopathy (Figure 1) or epithelial ingrowth under the LASIK flap was clearly shown by the high-resolution images with high magnification using SD-OCT.

The introduction of the 1310nm swept-source OCT, that is categorized as another type of Fourier-domain OCT, empowered us to reconstruct the 3D images of the anterior segment of the eye more precisely. For example the SS-1000 (Tomey Corporation, JAPAN) has a vertical resolution of 10 µm with 30,000 A-scans per second for 16mm diameter.

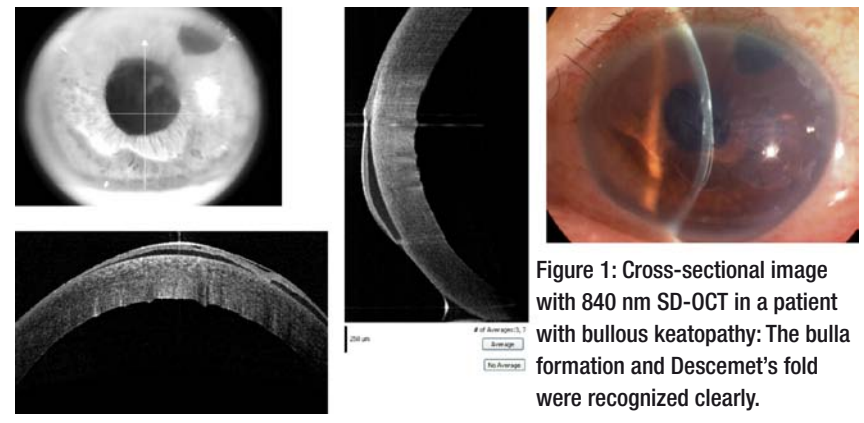
Figure 1: Cross-sectional image with 840 nm SD-OCT in a patient with bullous keatopathy: The bulla formation and Descemet's fold were recognized clearly.

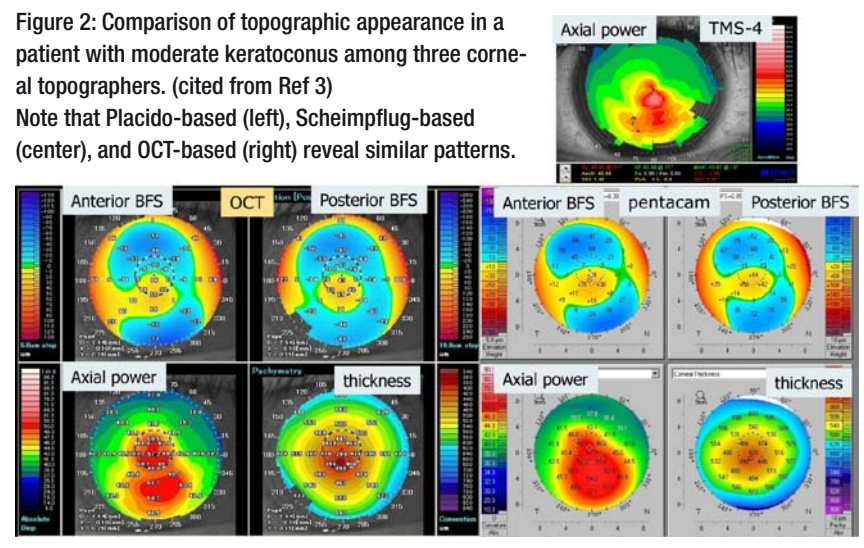

Figure 2: Comparison of topographic appearance in a patient with moderate keratoconus among three corneal topographers. (cited from Ref 3)
Note that Placido-based (left), Scheimpflug-based (center), and OCT-based (right) reveal similar patterns.

We had the chance to develop an OCT-based corneal topographer with the SS-1000 to solve problems of currently available corneal topographers[3,4]. Figure 2 shows the example how to compare topographic findings among a Placido-based corneal topographer (TMS-4N, Tomey), a Scheimpflug-based corneal topographer (Pentacam HR, Oculus), and a OCT-based corneal topographer (SS-1000, Tomey). In this eye with mild keratoconus, one can find all the anterior axial power maps revealed similar inferior steepening. Also, elevation maps of the anterior and posterior corneal surfaces and the pachymetry map resemble each other between Pentacam and SS-1000.

The Placido-based topographer uses mire images produced by the reflex in pre-corneal tear film and it is difficult for the videokeratoscope to digitize heavily distorted mire images in eyes with severe irregular astigma-

continued on page 11

continued from page 10

tism. The OCT-based topographer is resistant to the severe distorted corneas because of the sequential acquisition of cross sectional images.

With the OCT corneal topographer, topographic analysis can be done even in the area where severe scar or edema exists in the corneal stroma. This may be the potential advantage of the OCT corneal topographer over conventional instruments in terms of the application for evaluating various types of corneal diseases or corneal surgeries. In addition, the OCT-based corneal topographer has the potential to analyze anterior and posterior parts of lamellar surgeries separately, as OCT can detect the interface following DSAEK, DALK, FLEK (Femto-second Laser enabled Keratoplasty), and LASIK (Laser in situ Keratomileusis).

The OCT technology will play a more and more important role as one of the most useful non-invasive and quantitative modalities for examining the anterior pathology of the eye, planning and evaluating anterior segment surgeries in the near future. ■

**Sat, 18 February 08.30 – 10.00 hrs**
**Hall 1**
**Session: COR - Advances in Corneal Imaging**

**Author:** Naoyuki Maeda, M.D.
Department of Ophthalmology
Osaka Univ. Graduate School of Medicine
Room J7, Yamadaoka 2-2
Suita, 565-0871, Japan
E-Mail: nmaeda@ophthal.med.osaka-u.ac.jp

## References

1. Huang D, Swanson EA, Lin CP et al: Optical coherence tomography. Science 1991;254(5035):1178-1181.
2. Izatt JA, Hee MR, Swanson EA et al.: Micrometer-scale resolution imaging of the anterior eye in vivo with optical coherence tomography. Arch Ophthalmol 1994;112(12):1584–1589.
3. Maeda N.: Optical coherence tomography for corneal diseases. Eye Contact Lens. 2010; 36(5):254-259.
4. Nakagawa T, Maeda N, Higashiura R et al.: Corneal topographic analysis in patients with keratoconus using 3-dimensional anterior segment optical coherence tomography. J Cataract Refract Surg 2011;37(10):1871-1878.

# Early Visual Rehabilitation Prevents Depression

## Results of a Randomized and Controlled Pilot Study in Patients with AMD

TÜBINGEN – Adequate and in-time vision rehabilitation has a positive effect on secondary depression due to AMD.

In several studies is was reported that age-related macular degeneration (AMD) has a negative impact on quality of life (Mitchell J et al., Health Qual Life Outcomes 2006;4:97; Wahl HW et al. Ophthalmologe 2008 105:735-743; Casten RJ et al. Curr Opin Ophthalmol 2004;15(3):181-183). It also often leads to secondary depressive disorders and to cognitive impairment (Augustin A et al. Invest Ophthalmol Vis Sci 2007;48(4):1498-1503; Pham TQ et al. Gerontol 2006;52:353-358; Rovner BW et al. Am J Geriatr Psychiatry 2009 17(7):574-81). If we have a look on the according data, we find that there is a prevalence up to 33 percent of AMD-patients who additionally suffer from depression. Depression itself even may deteriorate patients' perception and can worsen patients mental situation (Rovner BW et al. Arch Ophthalmol 2002; 120(8):1041-1044; Clemons TE et al. Arch Ophthalmol 2006;124(4):537-543).

**Members of he study group:**
[1]Mielke A, [2]Wirkus K, [2]Niebler R, [2]Eschweiler G, [1]Nyugen NX, [1]Trauzettel-Klosinski S
[1]Vision Rehabilitation Clinic and Research Lab, Centre for Ophthalmology, University of Tübingen, Germany
[2]Department for Psychiatry und Psychotherapy, University of Tübingen, Germany

The access to professional help such as psychological support or low vision rehabilitation in general is poor (Wahl HW et al. Ophthalmologe 2008 105:735-743). We decided to create a randomized controlled pilot study to investigate the influence of low vision rehabilitation on the occurrence of secondary depressive disorders related to AMD. For this study we cooperated with our colleagues in the Department of Psychiatry and Psychotherapy.

We included patients suffering from AMD in both eyes and best corrected visual acuity not better than 0.2 to make sure that reading was not possible anymore without low vision aids. None of the patients had undergone visual rehabilitation before. We recruited patients into two study arms: a rehabilitation group, which was provided with low vision aids at the first assessment, and a control group which was provided 3 months later at second assessment. All patients underwent clinical ophthalmological examination and psychological testing at first and second assessment. We measured reading speed of patients in the rehabilitation group at both assessments, of control group only at second assessment because the control group did not get rehabilitation before and therefore could not read at first assessment. Psychological testing was executed via Geriatric Depression Scale, German version of CES-D-Scale (ADSL: general depression scale), Mini-Mental State Examination, Dementia Detection Test and Quality of Life was determined by National Eye Institute Visual Function Questionnaire (NEI-VFQ 25).

We included 22 patients, who were randomly assigned: 11 were recruited for the rehabilitation group and 11 as controls. Average age was 79 (range 68-85) years. At first assessment there was no statistically significant difference between the two groups regarding age, gender, education, cognitive status, depression and quality of life.

Best corrected visual acuity did not change in the three months interval.

Reading speed in the rehabilitation group, as expected, improved in a clinically relevant matter from 44 words per minute up to 59 words per minute. Because of the small number of patients included, this difference did not become statistically significant.

In terms of the psychological testing we observed changes from visit one until visit two in three test items:

▶ Median of the ADSL was 3 points diminished in the rehabilitation group whereas it increased 3 points in the control group, which implies that patients of the rehabilitation group became less depressive whereas patients of the control group became even more depressive throughout the observation period (figure 1.).

▶ In the Dementia Detection Test scores increased 2 points in the rehabilitation group and diminished 3 points in the control group, meaning that patient's mental situation improved in the rehabilitation group.

▶ Also the subitem "exercise of social roles" of the NEIVFQ 25 changed in a divergent manner:

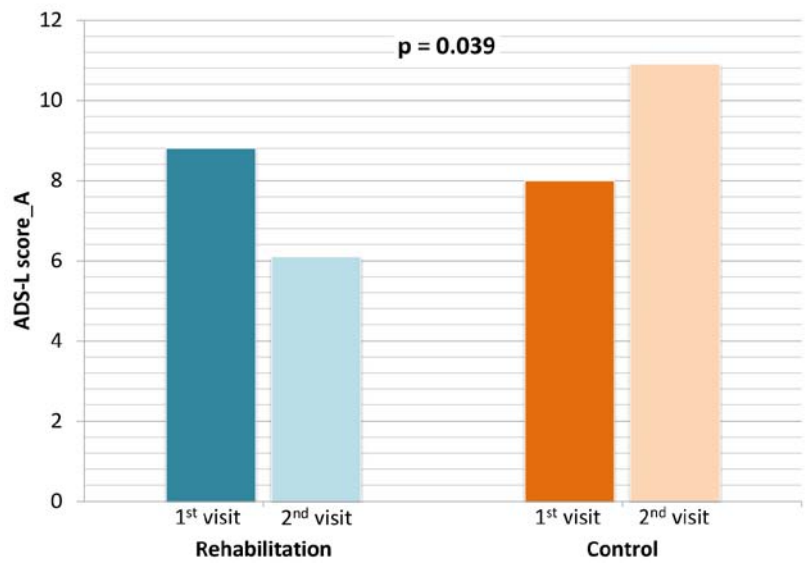


Figure 1: ADS-L score_A (general depression scale) at 1st and 2nd visit. The rehabilitation group became less, the control group more depressive. The interactive effect of change was statistically significant.

Dr. Anne Mielke (left), investigator and Prof. Dr. med. Susanne Trauzettel-Klosinski (right), supervisor and presenting author of the study.

Testscore increased 13 points in rehabilitation group and decreased 5 points in control group, denoting an upturn of coping with social roles in the rehabilitation group. The interactive effect of change was statistically significant in all items (ADSL Scale p = 0.039, Dementia Detection Test p = 0.037 and NEIVFQ 25 item "exercise of social roles p = 0.035), which implicates, that the rehabilitation does not only prevent a further decline into depressive symptoms but also is associated with an improvement in mood.

We found encouraging indications that adequate and in-time vision rehabilitation has a positive effect on secondary depression due to AMD. We are confident to confirm positive effects of visual rehabilitation after a longer observation period in the intended main study with a larger patient cohort. If we can again proof the prevention effect of visual rehabilitation on secondary depression this would be of a great social and economic relevance. ■

**Fr, 17 February 8.30 – 10.00 hrs**
**Conference Room B/C**
**Session: Depression and visual impairment**

**Authors:** Dr. Anne Mielke,
Prof. Dr. Susanne Trauzettel-Klosinski
Vision Rehabilitation Clinic and Research Lab
Centre for Ophthalmology
University of Tübingen, Germany
E-Mail: susanne.trauzettel-klosinski@med.uni-tuebingen.de

# Toric Multifocal IOLs or Bioptics?

## The Correction of Astigmatism in Cataract and Refractive Surgery

MANNHEIM - The correction of corneal astigmatism is a significant issue in cataract and refractive surgery.

Multifocal IOLs are designed to replace glasses. This necessitates a perfect refractive outcome, which means emetropia. To achieve good vision at distance and near, the refractive error must be within +/- 0.5 D, both for sphere and cylinder. Multifocal IOLs are thus much less tolerant to residual astigmatism than monofocal IOLs, which means that any astigmatism existing preoperatively or induced by the surgery must be addressed more precisely than in a monofocal IOL. As about 60-70% of eyes present with corneal astigmatism of more than 0.5 D before surgery, the correction of astigmatism is a significant issue both in cataract and refractive surgery.

### Which Technique is Preferable?

Corneal astigmatism can be corrected using corneal incisions, corneal laser refractive surgery such as PRK/LASEK or LASIK, and toric IOLs. Toric multifocal IOLs are now available from a number of companies including Alcon, Zeiss, and others. The question raised here is: Which technique is preferable? Shall we use a toric multifocal IOL or shall we combine laser refractive corneal surgery and implantation of a multifocal IOL, a technique named "bioptics"? Shall we use other options such as corneal incisions?

### Danger of Image Distortion

As always, there is no simple answer to this question, otherwise there would be no point in writing an article or giving a presentation on this topic! To start, let us remember that the astigmatism to be corrected is corneal. The crystalline lens is removed during the cataract or refractive lens surgery, which means any astigmatism present now must be corneal. It seems intuitive that corneal astigmatism should be corrected on the cornea, and optically speaking this is correct. Correcting corneal astigmatism on another plan, away from the cornea, induces image distortion. Just remember the image distortion that occurs when using spectacles to correct astigmatism as compared to contact lenses. The image distortion becomes more significant the higher the attempted correction is. If optics would be our only concern, correcting corneal astigmatism on the cornea would be ideal. But there are other issues.

### Possible Side Effects

First, there are the side-effects of laser refractive corneal surgery, namely dry eye syndrome in LASIK and haze in surface ablation. Second, performing laser refractive corneal surgery requires another surgical procedure, in addition to the IOL implantation. The patient has to come again, and there are the general risks of surgery. Thus, from an overall perspective, a toric

continued on page 12

continued from page 11

multifocal IOL seems to be an excellent choice to correct both astigmatism and sphere (and presbyopia, by the way).

### Use of the Femtosecond Laser

My current approach is a combination of the above and yet another technique. I implemented laser refractive lens surgery with an intraocular femtosecond laser in July 2011. I use the Alcon LenSx femtosecond laser, which enables me to perform corneal incisions both for entry into the eye and for astigmatism correction, capsulorhexis, and lens fragmentation and liquefaction. Using this femtosecond laser, I always position my main incision on the steep axis of the cornea (or at 12 o´clock, if there is no astigmatism present). I combine this main incision with an arcuate incision on the opposing half-meridian, or I use two arcuate incisions in addition to the main incision, if I place the main incision away from the steep meridian. The use of the femtosecond laser in lens surgery therefore enables me to correct corneal astigmatism by performing arcuate corneal incisions at the time of lens surgery. I use this approach routinely in eyes with corneal astigmatism of less than 2 D.

Corneal astigmatism of 2 D or more can still be corrected on the cornea using arcuate incisions alone, but the incisions will induce a significant amount of corneal irregularity as they are typically performed at a radius of 4.5 mm (9 mm diameter), or even less, and therefore not too far away from the center of the cornea. Because of this irregularity, I prefer to split the correction of corneal astigmatism of 2 D or more between corneal arcuate incisions and a toric multifocal IOL. For example, if corneal astigmatism of 3 D is present, I will implant a toric multifocal IOL, which corrects 1.5 D of astigmatism at the corneal plane, and I will use arcuate laser incisions to correct the remaining 1.5 D of corneal astigmatism. I believe that this approach minimizes optical side effects and maximizes predictability of refractive outcome.

What about bioptics? Is there still a place for laser refractive corneal surgery in combination with IOL implantation? I believe there is, although I do no longer use bioptics as a preplanned procedure if a toric multifocal IOL is available. In my opinion, bioptics is therefore indicated whenever a toric multifocal IOL is not available for the attempted correction, or in all cases of retreatments due to unexpected refractive outcome. The predictability of IOL calculation formulas is not 100%, the outcome of arcuate incisions varies considerably, and toric IOLs can, as of today, not be implanted "on axis" in all eyes. This results in a certain number of "not perfect" refractive outcomes, which need to be addressed. A corneal arcuate incision can, of course, be repeated, or enlarged, and a misaligned toric IOL can be rotated. Adding or enlarging an arcuate corneal incision, however, is not very predictable, and re-aligning a toric IOL requires another intraocular procedure. I therefore prefer to use laser refractive corneal surgery in these cases. Typically, I will perform LASIK with a femtosecond laser. I always place my arcuate incisions at a radius of 4.5 mm (9 mm diameter), which leaves space for an 8.5-mm flap, which is my preferred choice. I prefer LASIK, but this is a personal choice. PRK/LASEK work just as well and will give the same results.

### Conclusion

In summary, bioptics are the better choice from a purely optical perspective, as corneal astigmatism is corrected at the corneal plane. However, toric multifocal IOLs are the preferred option, because they require one surgical procedure only in most eyes and still provide an excellent refractive outcome. Toric multifocal IOLs may be combined with corneal relaxing incisions (e.g., laser refractive lens surgery with a femtosecond laser) to minimize optical side effects and maximize refractive outcome. ■

**Thu, 16 February 13.00 – 14.30 hrs**
**Hall 1**
**Session: Presbyopia correction: where are we?**

**Author:** Michael C. Knorz
Professor of Ophthalmology
Medical Faculty Mannheim
of Heidelberg University
Mannheim, Germany
E-Mail: knorz@eyes.de
Dr. Knorz is a consultant to Alcon LenSx, Ft. Worth, TX, USA

# Management of Complicated Femtosecond Laser Flaps

## Problems often Linked to the Surgical Technique

IZMIR – The femtosecond laser has documented advantages in creating the corneal flap. Complications are rare and not as devastating as some of microkeratome-associated complications.

The most crucial step in LASIK is the creation of the corneal flap, as anything less than a perfect flap jeopardizes the success of the operation. Although the microkeratome has long been used successfully for flap creation, recently, the femtosecond laser has found extensive use for corneal flaps. Having had excellent results with the microkeratome in our clinic, we initially felt that we did not need the femtosecond laser. However, a few weeks after the installation of the femtosecond laser we were so pleased with its results that it became our method of choice, leaving the microkeratome as a backup instrument. The femtosecond laser has documented advantages over the microkeratome. Mainly, it is more precise and predictable, also the complications associated with the femtosecond laser are not as devastating as some of the complications associated with the microkeratome. Our experience is limited to the IntraLase FS 30 and the IntraLase FS 60 (Abbott Medical Optics, Santa Ana, CA).

### Suction Loss

This is an occasional complication where the suction ring loses vacuum during the flap creation. Tight orbits, lid squeezing and faulty positioning are the main causes. If suction loss happens during the raster phase, we reapply a different suction ring and the same cone and repeat the procedure. If the suction is lost during the side cut we repeat the side cut only by reducing the diameter by 0.2 mm, using the same cone and a different suction ring. Sometimes the suction is lost during the last second of the side cut. In this case we do not repeat the side cut, because in our experience, the side cut is almost always sufficient. In two cases I was unable to achieve suction in spite of several attempts. In these cases, I performed the cut by increasing the pressure and manually holding the suction ring without any complications.

### Gas Bubbles

The most common problem is the opaque bubble layer which interferes with the laser auto tracking. In these cases, it is best to wait until the bubble layer diminishes to a level which does not interfere with the excimer laser auto tracking. Gentle massage of the corneal surface with a spatula may shorten the time by helping the absorption of the bubbles. Sometimes the gas bubbles find their way into the anterior chamber by dissecting through the cornea and trabecular meshwork. These bubbles, because of the supine position of the patient interfere with the patient fixation and the laser autotracking. In such cases simple dilatation of the pupil usually solves the problem with the auto tracking, or one can wait a few hours or ask the patient to come the next day.

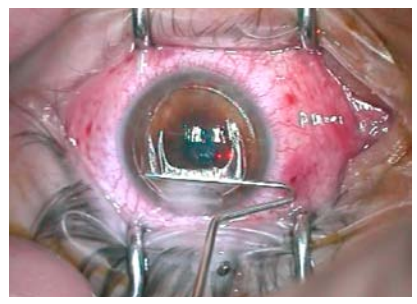

Flap side tear.



Raster phase in a case with previous keratoplasty.

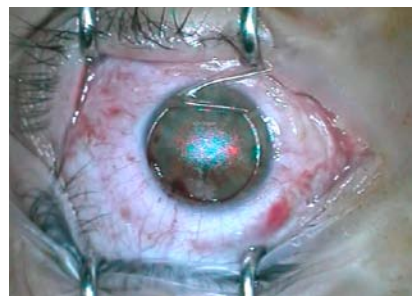

Inferior hinge in a case with the hinge tear.

Vertical gas breakthrough may happen in corneas with scars that caused a physical defect on the Bowman's membrane. During the femtosecond raster phase, this can be recognized as a black spot. We avoid lifting such flaps to prevent buttonholes. The best method of avoid vertical gas breakthrough is to make the flap thicker. If the scar is not recognized preoperatively and the flap is lifted causing a button hole, after the excimer laser, the flap is repositioned and carefully dried then a contact lens is applied. We have had several such cases without any negative consequences.

### Flap Tears

The most serious complication associated with the femtosecond laser flaps is cutting the flap with the spatula. This is usually a surgeon-related complication. To prevent this one should check the tip of the spatula carefully for any defects before entering the interface. If this happens peripherally it has no effect on the vision of the patient. However, if the flap cut is at the pupillary axis, it compromises the visual quality. In such a case, the flap should be placed and dried carefully. After making sure that it is well adhered, a contact lens is placed on the cornea. In anticipation of such a complication, the surgeon should separate the flap as a whole or if he or she prefers to separate at multiple sweeps, the tip of the spatula must avoid the visual axis.

Kaskaloglu (4)

Mahmut Kaskaloglu

### Hinge Tear

This can happen when the spatula is inserted at the interface to initiate the lifting of the flap. In such a case, I leave a thin island of unseparated flap near the hinge tear and separate the rest of the flap to prevent extension of the hinge tear. I separate this island after complete separation of the flap then place the hinge and dry the edges. If the hinge is totally torn, the flap is separated in such a way that a hinge is left at 180 degrees from the original hinge.

### Incomplete Side Cut

The reason for this complication is the uneven cone position in the suction ring, causing uneven applanation during the procedure. The surgeon can notice this during the laser application or later at the excimer laser while lifting the flap. In our practice, if the partial cut is less than 45 degrees, we do not attempt a second side cut, even if we see it during the flap creation. Instead, we dissect the flap from where the side cut is proper and then carefully lift the uncut portion with the aid of a McPherson forceps. This is not as difficult as it sounds because there usually is a partial side cut. Although the relatively irregular edges increase the risk of epithelial ingrowth, we have not seen any.

### Decentered Flap

Extreme attention should be paid to center the flap on the cornea. Marking the center of the cornea before applying the suction ring helps to better centration, however it is possible to achieve perfect centration without marking.

Since the femtosecond corneal flaps are usually over 9mm, only extreme decentration can be clinically significant.

### Previous Penetrating Keratoplasty and RK

It is possible to make femtosecond laser flaps larger or smaller than the graft in corneas with previous penetrating keratoplasty. Lifting the flap in cases where the flap is larger than the graft and in corneas with RK is the most difficult part because the graft interface or RK incision may separate. One should dissect the flap very carefully in order to preserve the integrity of the cornea. If vertical gas breakthrough happens at the site of RK cuts, lifting the flap is not recommended because of the risk of a button hole.

### Unliftable Flap and Nondissected Islands

This is a rare complication where the interface is insufficiently dissected and it is difficult to separate the flap. It may be possible to separate the flap using a little bit more force during the lifting. Using too much force should be avoided since it may cause a rupture of the flap. In such cases it is advisable to postpone the surgery to a later date and attempt again with the femtosecond laser or the microkeratome.

### Conclusion

The complications of femtosecond laser flaps are rare and they can usually be handled by the surgeon without further consequences for the patient. These complications are not related to the femtosecond laser instrument but to the surgeon. The application of good surgical technique usually prevents such complications.

**Sat, 18 February 10.30 – 12.00 hrs**
**Hall 7**
**Session: IVI - Refractive surgery: complications and management**

**Author:** Prof.Dr.Mahmut Kaskaloglu
Kaskaloglu Eye Hospital
1400 sokak 10
Alsancak,Izmir,Turkey
E-Mail: mahmut@kaskaloglu.com
www.kaskaloglu.com